

# An Innovative Thread-looping Method for Facial Rejuvenation: Minimal Access Multiple Plane Suspension

Chao-Huei Wang, MD  
Heng-Jen Liu, MD  
Yun-Ta Tsai, MD  
Hsin-I Lin, MD  
Po-Yi Wu, MD  
Jheng-Wei Lin, MD

**Background:** Management of facial rejuvenation has evolved over past decades. Facelift with barbed suture is a minimally invasive surgical technique for facial rejuvenation. This study examined the efficacy and associated complications of a new thread-looping procedure called minimal access multiple plane suspension.

**Methods:** A total of 103 thread lifts were performed between 2014 and 2017. Patient satisfaction and adverse effects were evaluated.

**Results:** In the majority of patients (88/103, 85.4%), the results obtained were considered satisfactory 3 months after the procedure. The incidence of complications was low. Only 5.8% of the patients had slight postoperation asymmetry that was easily corrected. Minor complications experienced by patients included palpable suture knots (12.6%), persistent facial swelling (7.88%), and facial dimpling (2.9%). The causes of procedure-related complications were reviewed and discussed.

**Conclusion:** Reinforced by select anchoring points, "minimal access multiple plane suspension" suspends ptotic anatomic tissues, serving as an effective facial rejuvenation procedure with minimal downtime and satisfactory cosmetic results. (*Plast Reconstr Surg Glob Open* 2019;7:e2045; doi: 10.1097/GOX.0000000000002045; Published online 7 January 2019.)

## INTRODUCTION

Facial aging is inevitable and cannot be stopped. With the increase in age, the face sags, and appears tired and volume-depleted. Changes of the face are not due to a single factor but a whole layer problem.<sup>1-8</sup> Aging changes include the skin, subcutaneous tissue, muscle, and bone.<sup>5,7,9-14</sup> It is now known that facial fat pads and retaining ligaments also play a role in aging of the face.<sup>15-19</sup> To address the problem, a comprehensive understanding of the pathogenesis of facial aging based on anatomy is important.

Previous studies have focused on the superficial musculoaponeurotic system (SMAS) interventions to restore a youthful face.<sup>20,21</sup> Several facelift techniques, including SMASectomy, SMAS plication, and deep plane rhytidectomy

have been advocated.<sup>22-26</sup> However, a limited effect on the nasolabial fold was seen, except in extended SMAS procedures. Barton<sup>27,28</sup> described the high-SMAS technique in 2002 and a visible improvement in the nasolabial fold was observed. Although good postoperative results have been achieved with different facelift techniques, the recovery period is long. Moreover, a scar on the face, despite a minimal incision, is a major concern among Asians. Tonnard et al.<sup>29</sup> advocated minimal access cranial suspension (MACS) lift in 2002. This technique involves a horizontal plane of purse-string suture with anchoring points in the deep temporal fascia. With the development in the facelift techniques, a shorter recovery period with good results is important.

In recent years, barbed thread technology has been used for facial rejuvenation.<sup>30-35</sup> With minimal trauma to the face, these techniques can be performed in a short time with early recovery and without scars. However, the effects are short-lasting and nearly one-third of the patients need a revision cosmetic surgery 8-9 months later.<sup>36</sup> Moreover, the detailed anatomic passage of the barbed thread was seldom discussed in the previous literature.

From the Dr. Shine Clinic, Taiwan.

Received for publication August 4, 2018; accepted October 10, 2018.

Presented at the Aesthetic Medicine World Congress Asia (AMWC Asia) & Taiwan Dermatology Aesthetic Conference (TDAC) 2018 in Taipei, Taiwan.

Copyright © 2019 The Authors. Published by Wolters Kluwer Health, Inc. on behalf of The American Society of Plastic Surgeons. This is an open-access article distributed under the terms of the Creative Commons Attribution-Non Commercial-No Derivatives License 4.0 (CCBY-NC-ND), where it is permissible to download and share the work provided it is properly cited. The work cannot be changed in any way or used commercially without permission from the journal.  
DOI: 10.1097/GOX.0000000000002045

**Disclosure:** The authors have no financial interest to declare in relation to the content of this article. The Article Processing Charge was paid for by the authors.

Supplemental digital content is available for this article. Clickable URL citations appear in the text.

Despite the trend of minimal trauma for management of the soft facial tissue, manipulation of the SMAS is still the key to good aesthetic outcomes and longevity. Pulling the SMAS at the vector of the zygomatic major muscle could provide a good lifting effect to the ptotic soft tissue; however, this is secondary to the movement of the SMAS (Fig. 1A, B). Loosening of the suture and diminishing elasticity of the SMAS weaken the pulling force on the ptotic tissues when using sutures for SMAS plication. Most previous techniques apply the lifting force on a single plane via the SMAS layer; however, this may not be sufficient for patients with excessive facial soft tissue. Therefore, we devised a novel thread-lifting procedure with a multi-planar suspension route with SMAS as an alternative option for Asian patients requesting facial rejuvenation without operative scars (Fig. 1C). We discuss the procedure with comprehensive details in this article.

We used a minimal access multiple plane suspension (MAMPS) technique. It is a minimally invasive procedure and targets the drooping tissues with good anchoring points. With a good knowledge of anatomy, the procedure can be performed smoothly with a short recovery time.

## MATERIALS AND METHODS

### Patient Assessment and Selection

A thorough preoperative evaluation is vital to ensure a favorable outcome. The patient's history should be reviewed for comorbidities such as cardiovascular disease, cerebrovascular diseases, major organ dysfunction, and any potential healing impairment, which may preclude safe surgery. Untreated hypertension should be medically controlled before the surgical procedure. Use of anticoagulants should be discontinued 1 week before the surgery to minimize intraoperative bleeding and postoperative hematoma formation. However, if the patient has a preceding history of acute myocardial infarction, the aspirin regimen should not be disrupted.

The patients should be educated that aging occurs concurrently across all the structural layers of the face including the skin, subcutaneous tissues, SMAS, retaining ligaments and bones. Without maintenance effort, progressive weakening of the underlying layers further causes displacement of the intervening fat-pad. These lead to a sagging midface, cheeks, and jawline. Establishing a mutual understanding of the facial aging theory helps the patient reach a more realistic goal without unrealistic expectations. Subsequently, a panfacial analysis of the

patient's overall skin laxity, skeletal shape, facial contour, and subcutaneous volume should be conducted for a harmonic facial rejuvenation outcome.

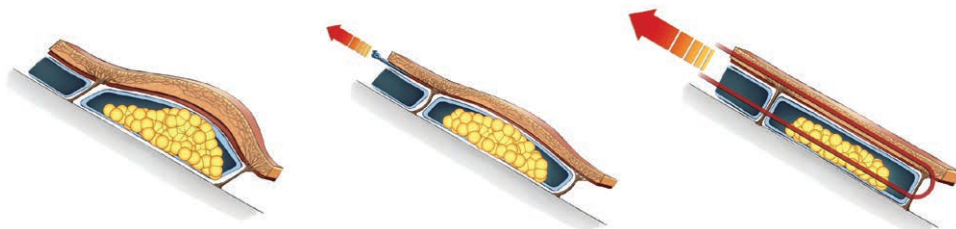Indications for MAMPS include (1) Patients without redundant skin seeking facial rejuvenation without operative scars and longer lasting effect. (2) Younger patients with a puffy cheek seeking a V-shaped aesthetic youthful face. (3) Patients with a keloid scar seeking improvement of aging without surgery. Facelift surgery should be advised for patients with excessive skin laxity to reposition the skin and subcutaneous tissue as a single unit. Individuals with poor skeletal support might require facial implants to the cheek to provide longer support for tissues that have been lifted.

### MAMPS SURGICAL TECHNIQUE

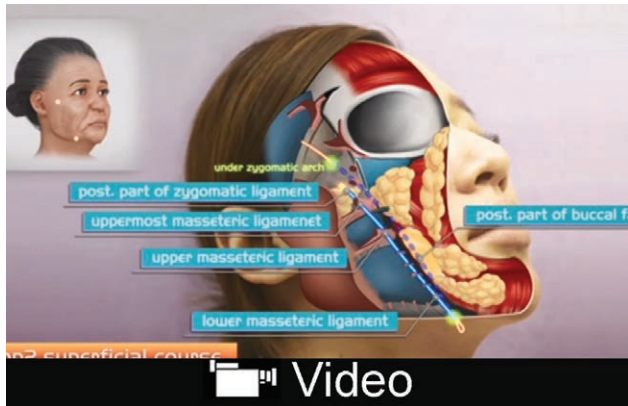
MAMPS can be performed under general anesthesia or under sedation on an outpatient basis. Patients also receive local anesthesia containing 2% lidocaine with epinephrine (1:10000) over the designated puncture sites including the temporal region, canine fossa, submandibular region, and the mastoid process. Collectively, less than 15 cc tumescent is infused over the face. To ensure an accurate intraoperative facial judgment, an additional 20-minute wait-time after tumescent infiltration is recommended. This reduces the unnecessary swelling and prevents excessive bleeding during the procedure.<sup>37</sup>

MAMPS is modeled on the techniques of surgical facelift and thread-lift. Choices of vector directions, anchor points, and targeted loosening of the anatomic structures are the key to achieving an effective and long-lasting outcome. It is imperative to have experienced and sensitive hands for handling the cannula or blunt needle with great control. Operators must be familiar with the resistance encountered while maneuvering the cannula through the different tissue types. Generally, resistance is rare when the cannula penetrates a space. The resistance is strong with a tendency to stall as the cannula penetrates the ligaments. Change in the resistance from strong to minimal is a sign of penetrating the fat pads.

There are 2 parts of MAMPS: a tri-loop for the facelift of the lower two-thirds followed by an ancillary postauricular double-loop for jaw line enhancement (see video, Supplemental Digital Content 1, which displays surgical techniques of thread-looping method "MAMPS." This video is available in the "Related Videos" section of the Full-Text article at PRSGlobalOpen.com or at <http://links.lww.com/PRSGO/A929>).



**Fig. 1.** A, Aging of facial structure with ligament loosening and fat pad ptosis. B, Effect of pulling SMAS with ptotic tissue lifting indirectly. C, Effect of pulling multi-layer of ptotic tissue directly.



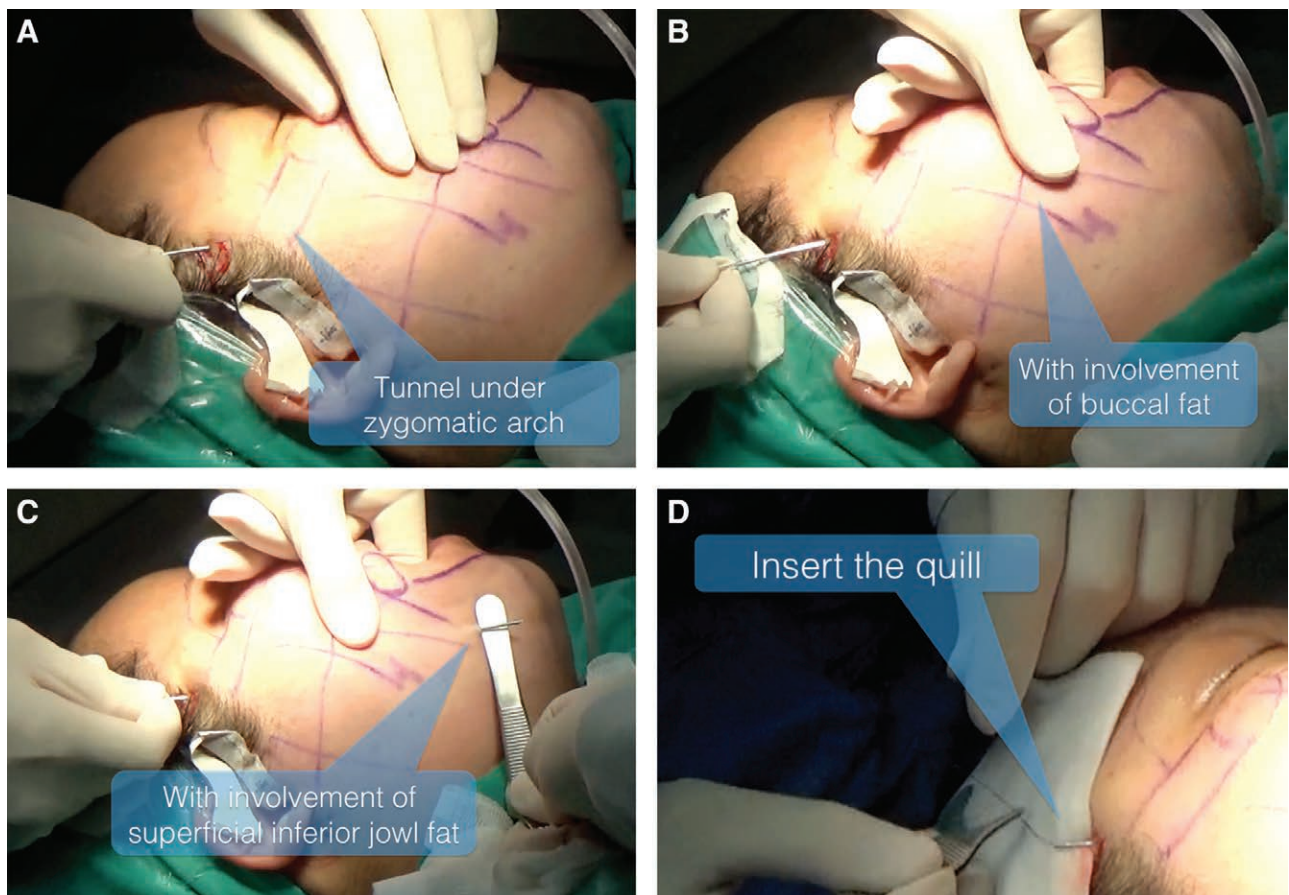
**Video Graphic 1.** See video, Supplemental Digital Content 1, which displays detailed surgical techniques of thread-looping method “MAMPS.” Choices of vector directions, anchor points, and targeted anatomic structures are well illustrated. MAMPS includes a tri-loop for the lower two-thirds facelift followed by an ancillary postauricular double-loop for jaw line enhancement. This video is available in the “Related Videos” section of the Full-Text article at PRSGlobalOpen.com or at <http://links.lww.com/PRSGO/A929>.

**First Loop**

Identify the zygomatic eminence and modiolus. The first loop suspension will follow the direction of the line connecting the above landmarks, which is parallel to the zygomatic major muscle. A 0.8-cm incision is made along the temporal hairline 1 cm above the zygomatic arch, followed by a deep dissection till the deep temporal fascia with a blunt scissor. The cannula is inserted under the zygomatic arch (Fig. 2A) and maintained at the deeper level as it passes toward and loops through the buccal fat pad (Fig. 2B). The cannula exits through the lower mandibular border to loop through the inferior jowl fat superficially (Fig. 2C). No. 2 Quill monoderm (Angiotech Pharmaceuticals, Inc, Vancouver, British Columbia, Canada) is inserted (Fig. 2D) as a looping material. For the return loop, the cannula is reinserted at the same exit point, staying above the SMAS layer and looping through the zygomatic ligament. It crosses over the zygomatic arch exiting at the same entry point and knots are tied.

**Second Loop**

The anterior border of the masseter muscle is identified. The cannula is inserted through the same entry point as the



**Fig. 2.** Detailed steps of loop 1 deep course with suture passing through the cannula on its ingress and egress. A, The deep course of first loop goes under the zygomatic arch. B, With the assistance of left hand to press the buccal mucosa would be helpful to feel the tract of cannula. C, After feeling the course of the cannula passing through the buccal fat, using left fingers to compress buccal area soft tissue could guide the cannula superficially to the egress with involvement of superficial jowl fat. D, Insert quill into the cannula.

first loop. It is passed deep under the zygomatic arch and vertically down the anterior border of the masseter muscle to loop through the posterior portion of the buccal fat pad. The cannula exits through the lower mandibular border. The quill is then inserted. For the return loop, the cannula is reinserted at the same exit point. Staying above SMAS layer and looping through the lower, upper, and uppermost masseteric ligament as well as the zygomatic ligament, the cannula is crossed over the zygomatic arch exiting at the same entry point and knots are tied.

**Third Loop**

The zygomatic minor vector from the zygoma to the nasal alae is identified. The cannula is inserted through the same entry point as the first loop, staying superficial to the zygomatic arch to loop through the zygomatic cutaneous ligament. Following the zygomatic minor vector, the cannula is pushed deeper to loop through the deep medial cheek fat. The cannula exits lateral to the nasal ala and the quill is inserted. For the return loop, the cannula is reinserted at the same exit point, staying above the SMAS layer and looping through the zygomatic ligament and crossing over the zygomatic arch exiting at the same entry point. Knots are tied to the second loop.

**Ancillary Postauricular Loops**

The guiding hook with the attached quill is navigated through the dense tissue of the mastoid process. A tunnel is created from the lower (point A) to upper (point B) portion of the mastoid process. The incision is elongated in advance at point B vertically upward for an additional 0.5 cm to bury the subsequent sutures. The cannula is inserted from point A, staying in the supraplatysmal plane toward the mentum, to loop through the mandibular ligament near the lower mandibular margin. It is advanced further, with involvement of the inferior jowl fat and back. It is looped through the Lore’s fascia and exited through point B. The cannula is reinserted and advanced antero-inferiorly along the risorius muscle, exiting 1 cm lateral to the modiolus and back. It is looped through the Lore’s fascia and exits through point B. Knots are tied at point B.

**POSTOPERATIVE CARE**

All the Quill sutures are buried under the subcutaneous tissue. The incision wound is closed with 3 interrupted sutures using 6-0 nylon. Since it is a minimally invasive procedure, no drain placement is required. Postoperative ice pack is applied for 1 day. The patient is discharged 2 hours after the procedure with oral antibiotics and analgesics. Soft food intake is advised for the first 24 hours after the surgery. Sutures are removed after 1 week.

**EVALUATION OF THE SATISFACTION RATE**

Anonymous patient satisfaction ratings were collected in person at the first follow-up (1 week after MAMPS) and during the second visit (3 months after MAMPS). Using the Likert scale, patients rated the cosmetic result as very unsatisfied, unsatisfied, neutral, satisfied, or very satisfied (Table 1).

**Table 1. Patient Satisfaction Score after MAMPS**

	Very Unsatisfied (%)	Unsatisfied (%)	Neutral (%)	Satisfied (%)	Very Satisfied (%)
Postoperative 1 wk	0	10 (9.7)	19 (18.4)	14 (13.6)	60 (58.3)
Postoperative 3 mo	0	3 (2.9)	12 (11.7)	18 (17.5)	70 (68.0)

**RESULTS**

Between April 2014 and March 2017, 103 MAMPS lifts were performed (90 women, 13 men). The mean age was 56.5 years (range, 39–75 years). All procedures were performed under general anesthesia, in an office setting. Thirty-seven underwent MAMPS lift with simultaneous facial fat grafting. During the first 3 days, all patients had a marked swelling over the cheek area and restricted opening of the mouth. All patients had bilateral swelling of the cheeks, which subsided completely within 2–4 weeks in most of them. Eight patients had persistent facial swelling that resolved after more than 4 weeks; in 3 of them, the swelling subsided after more than 4 months. The longest duration of the swelling was 10 months. All patients were able to return to their normal activities immediately after surgery. Six patients complained of asymmetry of the face, which was easily corrected to satisfaction by another revision. Thirteen patients complained of palpable suture knots and the resulting stitch exposure, which required no surgical interventions. Three patients developed facial dimpling, which subsided within 4 weeks. No erythema or signs of infection were noted. All complications encountered are listed in Table 2. Most of the patients were satisfied with the final outcomes.

The overall satisfaction rate was 71.8% during the first week follow-up and 85.4% at 3 months follow-up (Table 1). Seventy-four patients rated the result as satisfactory at the first week follow-up, of which 60 (58.3%) were very satisfied and 14 (13.5%) were satisfied (Figs. 3, 4). Ten patients (9.7%) rated the results as unsatisfactory at the first week follow-up due to facial swelling or asymmetry. At the 3-month follow-up, 88 patients of MAMPS rated the result as satisfactory, of which 70 (68.0%) were very satisfied and 18 (17.5%) were satisfied. Three patients were unsatisfied with the final results (2.9%).

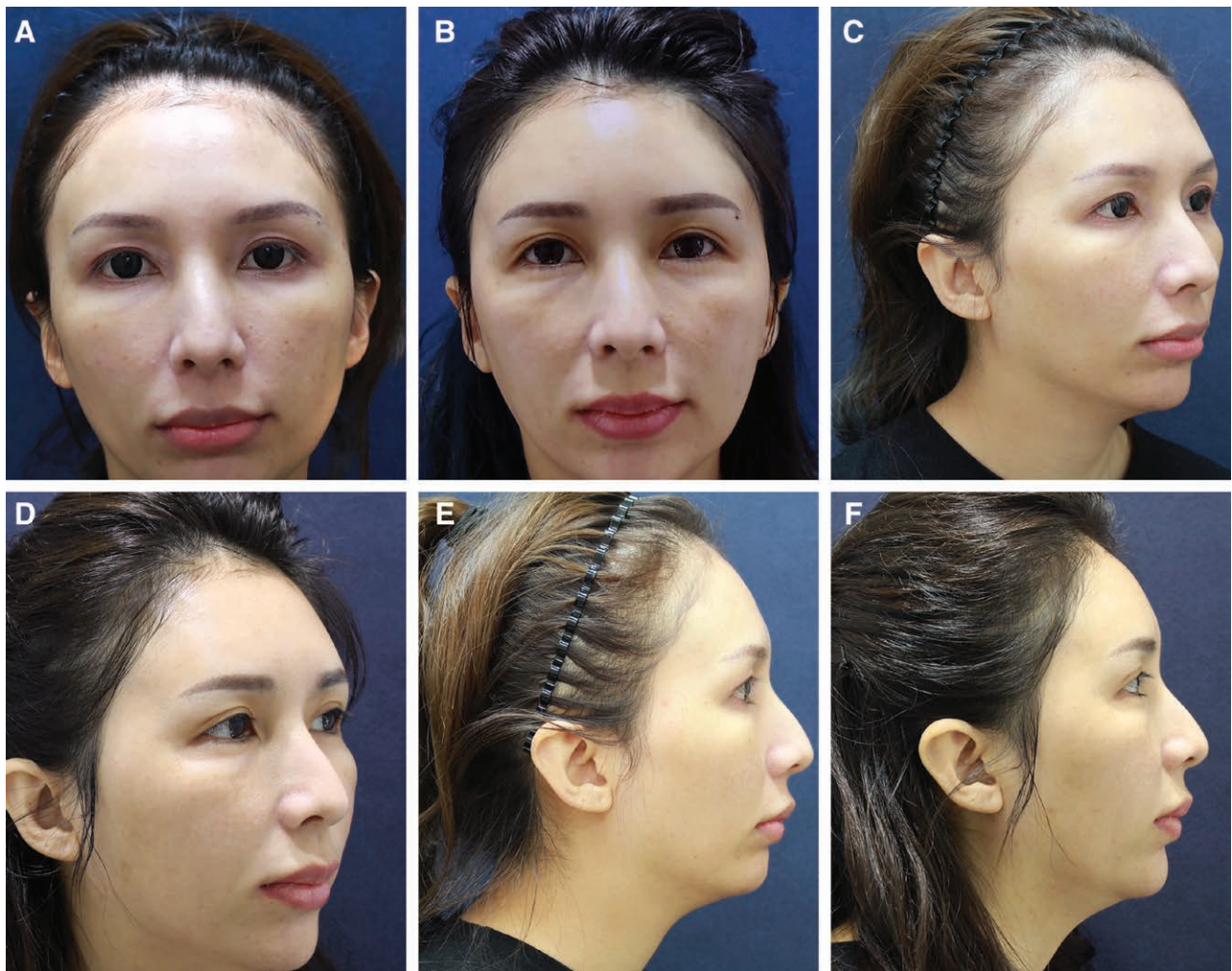The average follow-up period was 12 months. No patient asked for immediate removal of the threads for a few weeks postoperatively, and none developed any major complications.

**DISCUSSION**

In addition to skin elastosis, facial aging is a cumulative and multi-factorial process, encompassing skeletal

**Table 2. Complications in 103 MAMPS Cases**

Complications	No. Patients (%)
Palpable suture knots	13 (12.6)
Persistent facial swelling	8 (7.8)
Asymmetry	6 (5.8)
Facial dimpling	3 (2.9)

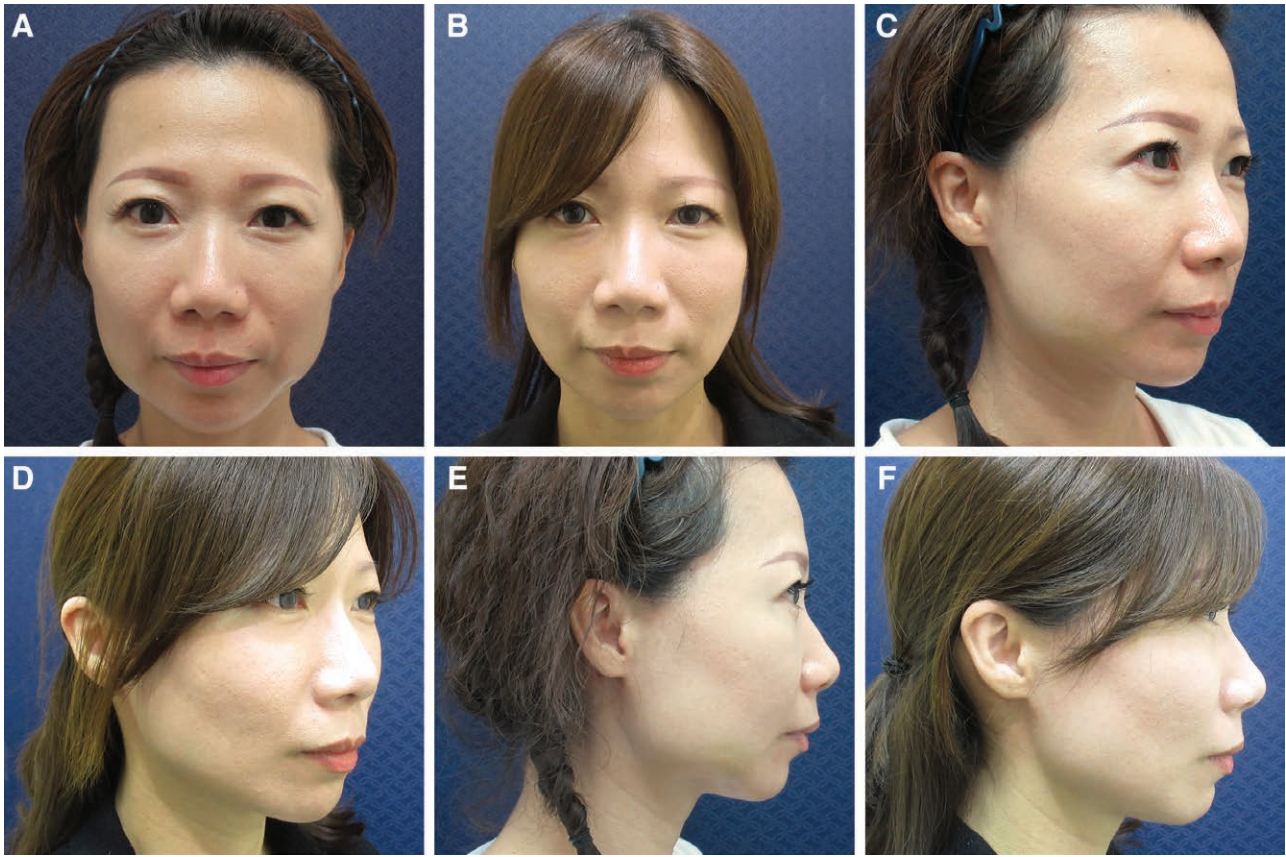

**Fig. 3.** A 32-year-old woman with mild ptosis of bilateral cheek fat who underwent MAMPS and 1 cc hyaluronic acid for chin augmentation. A, Preoperative frontal view illustrating ptosis of bilateral buccal fat and loss of inverted triangle of youthful face. B, Eight-months postoperative follow-up frontal view illustrating inverted triangle of youthful face. C, Preoperative three-quarter view. D, Postoperative 3-quarter view. E, Preoperative profile view. F, Postoperative profile view.

reabsorption, ligament loosening, muscle atrophy, and fat pad displacement. Concurrent loss of the underlying structural support across all 5 layers ultimately leads to overall facial laxity and change in contour. Additionally, gravity further causes the fat pads to descend, leading to deepening of the nasolabial folds and formation of the marionette line.<sup>38</sup> These changes affect the target areas that most patients are stressed about, namely, the sagging mid-cheek and droopy jowl. Since superficial fat pads that contribute to the facial contour are malleable, repositioning of the fat pads is imperative in facial rejuvenation. Facial rejuvenation has evolved from an invasive skin resection and redraping to less invasive procedures with a shorter downtime. We have presented here a minimally invasive procedure named MAMPS to re-suspend the focal ptotic fat pads.

MAMPS is a modified thread-lifting procedure that loops through various soft tissues at different layers. While the earlier facelifting techniques only indirectly lift the ptotic tissues by manipulating SMAS, the MAMPS

technique provides an en-bloc suspension of the soft tissues. Since collective suspension via multiple planes might be stronger than SMAS plication alone, a secure anchoring point is indispensable. Temporal fascia or Lore's fascia has been recommended as anchoring points by several facelift techniques. For heavy en-bloc tissue lifting, we selected the immobile zygomatic arch and periosteum of the mastoid process as anchoring points. Similar to other facial rejuvenation procedures, the thread-lifting suture technique also carries a risk of nerve injury. Hence, the loop course was designed based on Mendelson's theory of retaining ligaments and facial space to minimize the risk of nerve injury. In addition, tumescent fluid and a blunt cannula were used to prevent nerve injury and bleeding. The sutures were designed to hold tissues in a loop rather than at a single point. This allowed the suture tension to be evenly distributed, thus, reducing the possibility of tissue tear. The MAMPS suspension loop design achieves effective facial rejuvenation by using the zygomatic arch as a secure anchoring point, further minimizing the chances



**Fig. 4.** A 39-year-old woman with moderate midfacial ptosis and puffy lower face who underwent MAMPS. Follow-up photographs were taken at 9 months. A, Preoperative frontal view illustrating ptotic tissue over lower face. B, Follow-up frontal view illustrating improvement of puffy face, nasolabial folds, and marionette lines. C, Preoperative 3-quarter view. D, Postoperative 3-quarter view. E, Preoperative profile view. F, Postoperative profile view.

of loop loosening. Overall satisfaction rate with the final result was high. Nevertheless, most patients developed facial swelling, which gradually subsided over the first postoperative month. In 8 patients with persistent facial swelling, which did not subside within 1 month, the reason could be impaired lymphatic drainage due to the looping effect involving the regional lymphatic ducts. Gentle facial massage was recommended 1 month after the procedure; if performed immediately, it could be painful and the possibility of suture disruption is high.

Of the 103 patients, 13 reported palpable suture knots. Five patients reported palpable suture knots within 4 weeks postoperatively and were classified as the early group, while 8 cases reported the palpable suture knots more than 4 weeks postoperatively and were classified as the delayed group. The reason for early suture palpability was the insufficient depth of the knot placement. In the delayed group, the suture knots were at an adequate depth; however, multiple knots (more than 6) made them palpable.

The third common postoperative complaint was facial dimpling. One reason could be superficial tissue biting at the exit point. We recommend bites at the deeper subcutis, rather than at the dermis to reduce the possibility of skin dimpling. Dimpling could have also been

caused due to a kink resulting from the acute angle of the suture loop curvature. A more obtuse angle could have a smoother loop curvature, thus minimizing skin dimpling.

Compared with other techniques, MAMPS could be a good alternative for midface rejuvenation for patients who seek a shorter recovery time.

Traditional facelift focuses on lower face rejuvenation, whereas MAMPS encompasses both mid and lower face improvement. In the traditional facelift, patients undergo general anesthesia, and a prolonged recovery period of painful swelling. According to the principle of most facelift surgeries, manipulation of the SMAS should be parallel to the direction of the zygomatic major muscle. On the contrary, MAMPS thread-lift does not involve skin undermining. Hence, it significantly reduces postoperative swelling and anesthetic downtime. Although SMAS manipulation is best in parallel to the zygomatic major muscle, multi-directional suspension at different parts of the face can be considered, since the face is 3-dimensional. MAMPS provides the main suspension direction parallel to zygomatic major muscle and combines multi-directional suspensions for the local ptotic problems of the face. Thus, difficult areas such as the nasolabial fold can be corrected with a properly manipulated direction.

Over time, the buccal fat prolapses inferiorly below the level of the commissure into the lower face and overlies the anterior border of the lower masseter muscle. This results in an increased anterior prominence of the nasolabial fold and labiomandibular fold and jowl.<sup>38</sup> MAMPS thread-lifting re-suspends the deep medial cheek fat and buccal fat pad, thus improving the anterior ptosis. The traditional facelift approach, limited by the presence of rigid ligaments achieves only a mild improvement of the anterior face. Furthermore, MAMPS has an ancillary postauricular double loop design anchoring on the dense tissue of the mastoid process for reinforcing lower face rejuvenation.

Similar to the MACS lift principle, MAMPS is an anti-gravity thread-lift procedure to suspend the fat descent. However, instead of the horizontal plane looping, MAMPS incorporates a vertical loop through multiple layers of loosening soft tissues such as the inferior jowl fat, and masseteric, zygomatic, and mandibular ligament. Unlike the MACS, MAMPS does not undermine the skin; hence, the anterior facial venous and lymphatic supply is not compromised. The MAMPS procedure utilizes absorbable thread suture, taking bites at the descending fat pads and secures it through the rigid retaining ligaments and zygomatic arch. This provides effective traction of the midface and jowls, thereby lessening the nasolabial folds and marionette lines.

Using MAMPS, we could restore the aging changes caused by the loosening ligaments and the ptotic structure. However, for changes due to bone reabsorption or fat atrophy, fat grafting for volume augmentation is an option. In this study, 37 patients received MAMPS combined with fat transfer. All of them had satisfactory results. Thus, MAMPS lifts with fat transfer might be a good choice for complete facial rejuvenation. Besides the 37 patients who received fat transfer, 20 patients received poly-L-lactic acid injections and 33 patients received hyaluronic acid injections postoperatively. Sixty-eight of the 103 patients received onabotulinum toxin A injections within one year postoperatively.

Sutures are inherently conducive to thread-lifting downfalls and complications. Absorbable barbed suture lines might fracture and migrate, leading to abnormal traction lines. Although the MAMPS thread-lifting procedure provides acceptable improvements in the position of ptotic soft tissues, patients might experience minimal tenderness, palpability of the sutures, or knot extrusions.

The limitations of this study include its nonrandomized, retrospective case series design. There was no control group of patients treated with other rejuvenation procedures. The evaluation was based on the patients' satisfaction without any objective measurement and the period of evaluation was short. To understand the longevity of MAMPS, a prospective study with long-term follow-up after MAMPS would be planned.

## CONCLUSIONS

We described an innovative method effective for mid and lower face lifting called MAMPS. This is performed

as an outpatient procedure. Compared with other techniques, MAMPS is minimally invasive with lesser swelling and a shorter downtime. MAMPS secures loops around the zygomatic arch with different vectors to help suspend the ptotic structures, thereby improving the nasolabial fold and Marionette line. For candidates seeking optimal results in a limited recovery time, MAMPS could be a good option.

**Yun-Ta Tsai, MD**

Dr. Shine Clinic

6F., No.3, Sec. 1

Zhongshan Rd., Banqiao Dist.

New Taipei City 22063, Taiwan

E-mail: tuderek@gmail.com

## REFERENCES

- Hellman M. Changes in the human face brought about by development. *Int J Orthod.* 1927;13:475–516.
- Todd TW. Thickness of the white male cranium. *Anat Rec.* 1924;27:245–256.
- Lasker GW. The age factor in bodily measurements of adult male and female Mexicans. *Hum Biol.* 1953;25:50–63.
- Garn SM, Rohmann CG, Wagner B, et al. Continuing bone growth during adult life: a general phenomenon. *Am J Phys Anthropol.* 1967;26:313–317.
- Pessa JE, Zadoo VP, Mutimer KL, et al. Relative maxillary retrusion as a natural consequence of aging: combining skeletal and soft-tissue changes into an integrated model of midfacial aging. *Plast Reconstr Surg.* 1998;102:205–212.
- Pessa JE. An algorithm of facial aging: verification of Lambros's theory by three-dimensional stereolithography, with reference to the pathogenesis of midfacial aging, scleral show, and the lateral suborbital trough deformity. *Plast Reconstr Surg.* 2000;106:479–488; discussion 489.
- Kahn DM, Shaw RB Jr. Aging of the bony orbit: a three-dimensional computed tomographic study. *Aesthet Surg J.* 2008;28:258–264.
- Pessa JE, Chen Y. Curve analysis of the aging orbital aperture. *Plast Reconstr Surg.* 2002;109:751–755; discussion 756.
- Kahn JL, Wolfram-Gabel R, Boujrat P. Anatomy and imaging of the deep fat of the face. *Clin Anat.* 2000;13:373–382.
- Lambros V. Observations on periorbital and midface aging. *Plast Reconstr Surg.* 2007;120:1367–1376; discussion 1377.
- Montagna W, Carlisle K. Structural changes in ageing skin. *Br J Dermatol.* 1990;122:61–70.
- Wulf HC, Sandby-Møller J, Kobayasi T, et al. Skin aging and natural photoprotection. *Micron.* 2004;35:185–191.
- Gosain AK, Klein MH, Sudhakar PV, et al. A volumetric analysis of soft-tissue changes in the aging midface using high-resolution MRI: implications for facial rejuvenation. *Plast Reconstr Surg.* 2005;115:1143–1152, discussion 1153–5.
- Pessa JE, Chen Y. Curve analysis of the aging orbital aperture. *Plast Reconstr Surg.* 2002;109:751–755; discussion 756.
- Rohrich RJ, Pessa JE. The fat compartments of the face: anatomy and clinical implications for cosmetic surgery. *Plast Reconstr Surg.* 2007;119:2219–2227; discussion 2228.
- Rohrich RJ, Pessa JE. The retaining system of the face: histologic evaluation of the septal boundaries of the subcutaneous fat compartments. *Plast Reconstr Surg.* 2008;121:1804–1809.
- Wong CH, Hsieh MK, Mendelson B. The tear trough ligament: anatomical basis for the tear trough deformity. *Plast Reconstr Surg.* 2012;129:1392–1402.
- Furnas DW. The retaining ligaments of the cheek. *Plast Reconstr Surg.* 1989;83:11–16.

19. Wong CH, Mendelson B. Facial soft-tissue spaces and retaining ligaments of the midcheek: defining the premaxillary space. *Plast Reconstr Surg*. 2013;132:49–56.
20. Mitz V, Peyronie M. The superficial musculo-aponeurotic system (SMAS) in the parotid and cheek area. *Plast Reconstr Surg*. 1976;58:80–88.
21. Gosain AK, Yousif NJ, Madiedo G, et al. Surgical anatomy of the SMAS: a reinvestigation. *Plast Reconstr Surg*. 1993;92:1254–1263; discussion 1264.
22. Baker DC. Lateral SMASectomy. *Plast Reconstr Surg*. 1997;100:509–513.
23. Baker DC. Lateral SMASectomy. *Semin Plast Surg*. 2002;16:417–422.
24. Baker DC. Minimal incision rhytidectomy (short scar face lift) with lateral SMASectomy: evolution and application. *Aesthet Surg J*. 2001;21:14–26.
25. Baker DC. Minimal incision rhytidectomy (short scar face lift) with lateral SMASectomy. *Aesthet Surg J*. 2001;21:68–79.
26. Hamra ST. Composite rhytidectomy. *Plast Reconstr Surg*. 1992;90:1–13.
27. Barton FE Jr. The “high SMAS” face lift technique. *Aesthet Surg J*. 2002;22:481–486.
28. Barton FE Jr, Hunt J. The high-superficial musculoaponeurotic system technique in facial rejuvenation: an update. *Plast Reconstr Surg*. 2003;112:1910–1917.
29. Tonnard P, Verpaele A, Monstrey S, et al. Minimal access cranial suspension lift: a modified S-lift. *Plast Reconstr Surg*. 2002;109:2074–2086.
30. Villa MT, White LE, Alam M, et al. Barbed sutures: a review of the literature. *Plast Reconstr Surg*. 2008;121:102e–108e.
31. Atiyeh BS, Dibo SA, Costagliola M, et al. Barbed sutures “lunch time” lifting: evidence-based efficacy. *J Cosmet Dermatol*. 2010;9:132–141.
32. Sulamanidze MA, Shiffman MA, Paikidze TG, et al. Facelifting with APTOS threads. *Int J Cosmet Surg Aesthetic Dermatol*. 2001;4:275–280.
33. Paul MD. Bidirectional barbed sutures for wound closure: evolution and applications. *J Am Col Certif Wound Spec*. 2009;1:51–57.
34. Ruff G. Technique and uses for absorbable barbed sutures. *Aesthet Surg J*. 2006;26:620–628.
35. Paul MD. Barbed sutures in aesthetic plastic surgery: evolution of thought and process. *Aesthet Surg J*. 2013;33:17S–31S.
36. Garvey PB, Ricciardelli EJ, Gampfer T. Outcomes in threadlift for facial rejuvenation. *Ann Plast Surg*. 2009;62:482–485.
37. Gutowski KA. Tumescent analgesia in plastic surgery. *Plast Reconstr Surg*. 2014;134:50S–57S.
38. Zhang HM, Yan YP, Qi KM, et al. Anatomical structure of the buccal fat pad and its clinical adaptations. *Plast Reconstr Surg*. 2002;109:2509–2518; discussion 2519.