

A Simple and Scarless Method for Inframammary Fold Correction Using a Barbed Suture

Koichi Tomita, MD, PhD*
 Mifue Taminato, MD*
 Michiko Nomori, MD*
 Daisuke Maeda, MD, PhD*
 Shien Seike, MD*
 Hiroki Tashima, MD*
 Kenji Yano, MD, PhD†
 Tateki Kubo, MD, PhD*

Background: In the typical procedure for secondary correction of the inframammary fold (IMF) following breast reconstruction, a large incision is often required, and this increases surgical invasiveness. The “drawstring method” is a simple procedure for recreating a smooth IMF. We modified the drawstring method and developed an essentially scarless method for IMF correction from small stab incisions.

Methods: Patients at our hospital who presented with IMF ptosis or loss of definition after breast reconstruction and required IMF correction, as well as those who requested IMF recreation for the contralateral breast, during the period spanning May 2016 to June 2019 were considered for this study. We collected and analyzed demographic data, as well as complications and postoperative outcomes.

Results: The new method was performed on 20 patients, with the following breakdown: IMF recreation after breast reconstruction with a deep inferior epigastric artery perforator flap (11 patients), IMF recreation after breast reconstruction with a breast implant (2 patients), IMF recreation after breast reconstruction with fat graft (5 patients), and IMF recreation for the contralateral breast (2 patients). Overcorrection of the IMF stabilized by 2–3 months postoperatively, resulting in a smooth and well-defined IMF. For non–breast implant cases, the implant volume increased at the lower pole. Slack in the suture was observed in only 2 patients of the deep inferior epigastric artery perforator group and in 1 patient of the breast implant group after 6 months postoperatively.

Conclusions: Our new method allows for the recreation of an essentially scarless, smooth, and well-defined IMF. IMF definition can be adjusted by altering the depth of the barbed suture. Since this method can be performed under local anesthesia, it offers the benefits of reducing medical costs and physical burden on patients. (*Plast Reconstr Surg Glob Open* 2020;8:e2930; doi: [10.1097/GOX.0000000000002930](https://doi.org/10.1097/GOX.0000000000002930); Published online 16 June 2020.)

INTRODUCTION

The inframammary fold (IMF) provides inferior support for the breast and defines the overall breast shape and structure.¹ It is also important for a stable bra fit. IMF ptosis and loss of definition is often observed postoperatively, even if the IMF is recreated during breast reconstruction. The IMF can be recreated using the external approach (incision made from the outside)^{2,3} or the internal approach (fixation using sutures from within the

subcutaneous pocket).^{4–9} When secondary IMF correction is needed, these methods often require a large incision and thus are very invasive.

A number of recent reports have described IMF recreation using a barbed suture.^{10–12} Among these, the drawstring method reported by Terao et al¹¹ is a simple procedure that allows for the recreation of a smooth IMF and requires only a small incision, and adjustments in shape can be made in the sitting position after wound closure. Here, we modified the drawstring method and developed an essentially scarless IMF correction method using 4 small stab incisions. We describe our experiences with this new method on patients who required secondary IMF correction following breast reconstruction, as well as on those who desired IMF recreation for the contralateral breast.

From the *Department of Plastic and Reconstructive Surgery, Graduate School of Medicine, Osaka University, Osaka, Japan; and †Department of Plastic and Reconstructive Surgery, Osaka Breast Clinic, Osaka, Japan.

Received for publication February 27, 2020; accepted April 30, 2020.

Copyright © 2020 The Authors. Published by Wolters Kluwer Health, Inc. on behalf of The American Society of Plastic Surgeons. This is an open-access article distributed under the terms of the [Creative Commons Attribution-Non Commercial-No Derivatives License 4.0 \(CCBY-NC-ND\)](https://creativecommons.org/licenses/by-nc-nd/4.0/), where it is permissible to download and share the work provided it is properly cited. The work cannot be changed in any way or used commercially without permission from the journal.

DOI: [10.1097/GOX.0000000000002930](https://doi.org/10.1097/GOX.0000000000002930)

Disclosures: The authors have no financial interest to declare in relation to the content of this article.

Related Digital Media are available in the full-text version of the article on www.PRSGlobalOpen.com.

PATIENTS AND METHODS

Study Design

This study was approved by the Institutional Review Board of Osaka University. Patients who required IMF correction due to IMF ptosis or loss of definition after breast reconstruction, as well as those who requested IMF recreation for the contralateral breast, during the period spanning May 2016 to June 2019 were considered for this study. Surgery was performed under general anesthesia or local anesthesia. We collected data on demographics, timing of reconstruction (for flap surgery and breast implant cases), number of fat graft sessions (for fat graft cases), flap weight (for flap surgery cases), implant volume (for breast implant cases), follow-up period, and complications. We also assessed the postoperative outcomes using photographs taken at 6 months or later.

Surgical Procedure

The surgical procedure is demonstrated in the video (see Video [online], which displays intraoperative techniques for inframammary correction using our new method). Initially, stab incisions of 1–2 mm are made at about 2.5 cm intervals in 2 locations at the medial end of the planned IMF (Fig. 1A) (see Video [online], which displays intraoperative techniques for inframammary correction using our new method). A number 0 nonabsorbable barbed suture (V-Loc; Covidien, Mansfield, Mass.) is used to pierce the incision on the caudal-lateral side, and after piercing the costal cartilage, the suture exits through the incision on the cranial-medial side. The suture is then fixed to the costal cartilage by piercing the same incision and exiting through the incision on the lateral-caudal side, and finally passing the thread through the loop at the distal end of the suture. Important to note here is the complete removal of any adhesions between the suture and the tissue surrounding the stab incisions at the 2 locations (eg, using scissors). If this step is skipped, then skin distortions that appear when drawing the suture would remain. The subsequent steps are as described by Terao et al.¹¹ Briefly, after removing the suture needle, the external

cylinder of an epidural needle, which is bent along the IMF, is used to guide the suture along the superficial layer of subcutaneous fat in the lateral direction. During this, 2 additional stab incisions are made, 1 in the central region of the breast and the other in the lateral region of the breast (Fig. 1B). Where the IMF is shallow, the suture is passed through the deep layer, and where the IMF is deep, the suture is passed through the superficial layer, allowing for the fine-tuning of IMF definition. The suture path is 5–10 mm caudal to the planned IMF position at the central region of the breast (Fig. 1C). Preoperatively, we assess the resistance when pushing up the reconstructed breast by hand. If there is a strong resistance to turn back, we set the suture path more cranial. If the suture path is too caudal, slack in the suture can occur, and so caution is needed. Finally, after exiting the lateral chest, the suture is drawn in a slightly overcorrecting manner, cut, and buried under the skin. We usually do not change the degree of overcorrection depending on the cases, as excessive overcorrection causes slack in the suture.

To prevent postoperative slack in the suture, patients were instructed to wear supporting underwear for about 3 months to fix the IMF in position.

RESULTS

Patient characteristics are summarized in Table 1. The new method was performed on 20 patients, with the following breakdown: IMF recreation after reconstruction with a deep inferior epigastric artery perforator (DIEP) flap (DIEP group; 11 patients); IMF recreation after reconstruction with a breast implant (breast implant group; 2 patients); IMF recreation after reconstruction with fat graft (fat graft group; 5 patients); and IMF recreation for the contralateral breast (contralateral group; 2 patients). Median age and body mass index were 47 years (range, 39–67 years) and 21.8 (19.2–30.9), respectively, and the median follow-up period was 12 months (6–41 months). Median flap weight in the DIEP group was 365 g (220–650 g), and implant volumes for the 2 patients in the breast implant group were 270 and 410 ml. The IMF was created during the initial operation using the internal

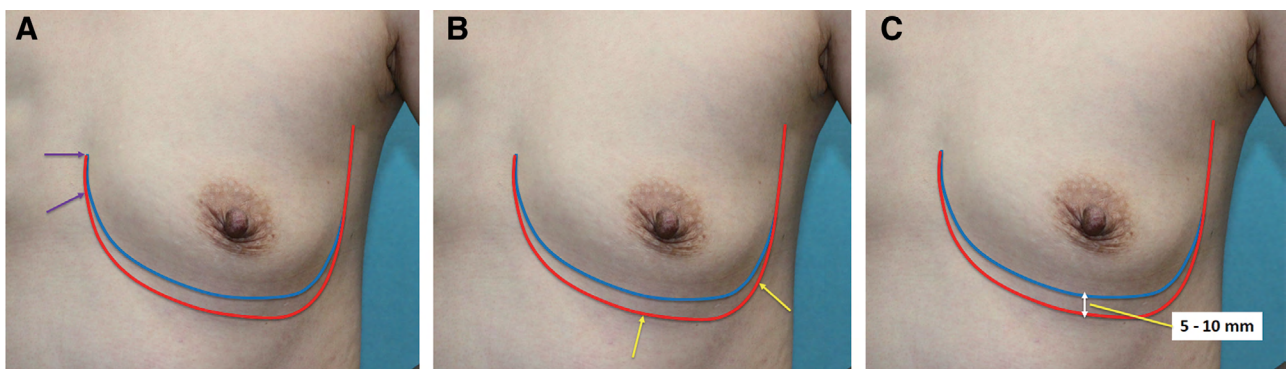


Fig. 1. Summary of IMF method. A, Stab incisions of 1–2 mm are made at about 2.5 cm intervals in 2 locations at the medial end of the planned IMF (arrows). B, Two additional stab incisions are made, one in the central region of the breast and the other in the lateral region of the breast (arrows), and an epidural needle is used to subcutaneously guide the suture in the lateral direction. C, The suture path is 5–10 mm caudal to the planned IMF position at the central region of the breast. Blue line represents planned IMF and red line represents path for passing the barbed suture subcutaneously.

Table 1. Patients' Characteristics

Patient No.	Reconstruction Procedure	Timing of Reconstruction or Number of Fat Graft Sessions	Age, y	BMI, kg/m ²	Flap Weight, g or Implant Volume, ml	Follow-up, mo	Complications	Suture Slack
1	DIEP flap	Immediate	51	19.2	238	24		
2	DIEP flap	2-stage, immediate	48	24.6	305	6		
3	DIEP flap	2-stage, immediate	49	22.6	308	41		
4	DIEP flap	Delayed	47	24	391	6		
5	DIEP flap	Delayed	67	24.4	365	12		
6	DIEP flap	2-stage, delayed	39	23.8	447	13		
7	DIEP flap	2-stage, delayed	45	23.5	415	20		Yes
8	DIEP flap	2-stage, delayed	55	20.3	300	12		
9	DIEP flap	2-stage, delayed	58	30.9	602	20		Yes
10	DIEP flap	2-stage, delayed	44	26.5	650	17		
11	DIEP flap	2-stage, delayed	47	21.9	220	6		
12	Breast implant	2-stage, immediate	49	19.5	270	10		Yes
13	Breast implant	2-stage, delayed	51	21	410	11	Subcutaneous induration of medial fixed portion	
14	Fat graft	3	46	21.5		24		
15	Fat graft	3	50	20.1		17		
16	Fat graft	3	47	20.2		7		
17	Fat graft	3	39	19.3		6		
18	Fat graft	4	46	22		12		
19	Contralateral		44	21.6		15		
20	Contralateral		42	20		12		

BMI, body mass index.

approach for all patients in these 2 groups. In the fat graft group, the IMF was corrected during the last session of fat grafting for all patients. For the 2 patients in the contralateral group, the procedure was carried out during reconstruction of the affected side with a fat-augmented latissimus dorsi myocutaneous flap.

Overcorrection of the IMF stabilized by about 2–3 months postoperatively, resulting in a smooth and well-defined IMF. In the non–breast implant groups, a substantial increase in implant volume was observed in the lower pole. After 6 months postoperatively, only 2 patients in the DIEP group and 1 patient in the breast implant group showed slack in the suture. Regarding complications, 1 patient in the breast implant group experienced subcutaneous induration of the medial fixed portion, which required a differential diagnosis from breast cancer. No other complications (including suture sinus formation) were noted.

CASE REPORTS

Case 1 (Patient No. 11; DIEP Flap Group)

A 47-year-old woman underwent 2-stage, delayed reconstruction with a DIEP flap after mastectomy for right breast cancer (Fig. 2A, B). As she presented with postoperative IMF ptosis, IMF correction using V-Loc was performed together with reconstruction of the nipple–areola complex. IMF symmetry was maintained at 6 months postoperatively (Fig. 2C, D).

Case 2 (Patient No. 13; Breast Implant Group)

A 51-year-old woman underwent 2-stage, delayed reconstruction with a Natrelle 410-ST-MX-410cc implant (Allergan, Inc, Irvine, Calif.) after mastectomy for right breast cancer (Fig. 3A, B). As she presented with postoperative IMF ptosis and loss of definition, IMF correction using V-Loc was performed together with reconstruction

of the nipple–areola complex. IMF symmetry was maintained at 11 months postoperatively (Fig. 3C, D).

Case 3 (Patient No. 15; Fat Graft Group)

A 50-year-old woman underwent 2 sessions of fat grafting (164 and 144 ml) after skin-sparing mastectomy for right breast cancer (Fig. 4A, B). IMF correction using V-Loc was performed during the third fat grafting session (122 ml). IMF symmetry was maintained at 9 months postoperatively (Fig. 4C, D).

Case 4 (Patient No. 19; Contralateral Group)

A 44-year-old woman planned to undergo delayed reconstruction with a fat-augmented latissimus dorsi musculocutaneous flap after nipple-sparing mastectomy for right breast cancer (Fig. 5A, B). The patient complained of uncomfortable bra fit, given the poor definition of the contralateral IMF. Thus, the contralateral IMF was recreated at the same time as breast reconstruction. IMF symmetry was maintained at 15 months postoperatively (Fig. 5C, D).

DISCUSSION

Although various methods for IMF recreation exist, including external and internal approaches, secondary correction is often required.¹ With autologous reconstruction, IMF ptosis or loss of definition can occur when the scar softens in the reconstructed breast, which includes the IMF. For reconstructions involving breast implants, the incidence of IMF ptosis is lower than with autologous reconstruction, but loss of definition of the IMF can occur due to capsule shrinkage around the implant.¹³

Less invasive methods for IMF correction after breast reconstruction are desirable. However, if the same method used during the initial operation to create the IMF is used, a relatively large incision would often be required. Especially, when internal approach is used in the initial operation, revision surgery becomes very invasive.

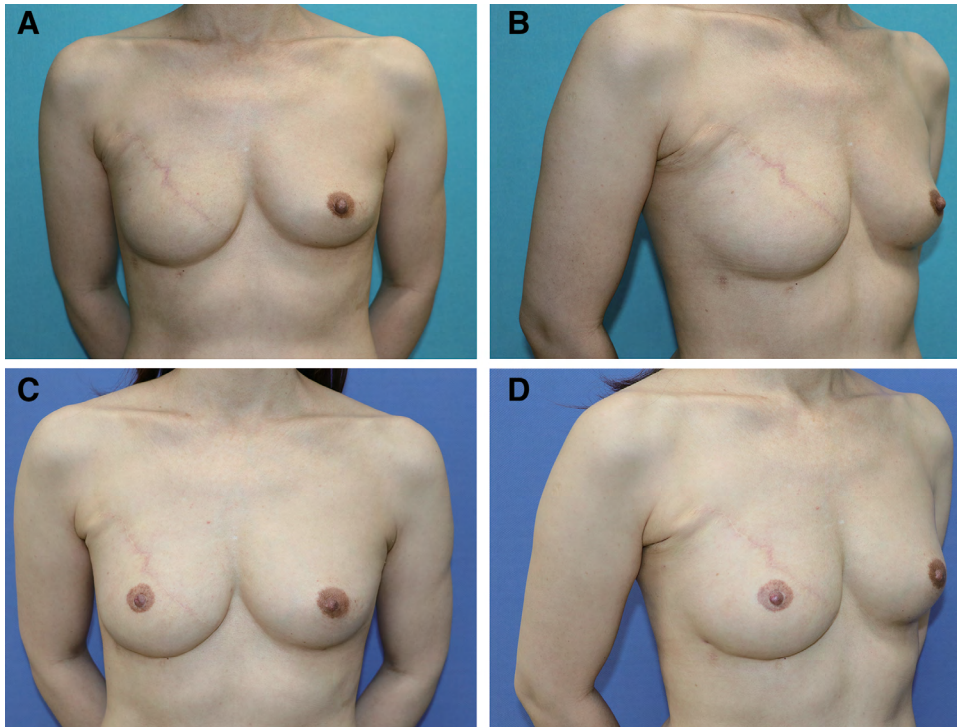


Fig. 2. A 47-year-old patient who underwent 2-stage, delayed reconstruction with a DIEP flap after mastectomy for right breast cancer. A, B, Preoperative photographs. IMF ptosis was noted. C, D, Photographs taken 6 months after corrective surgery.

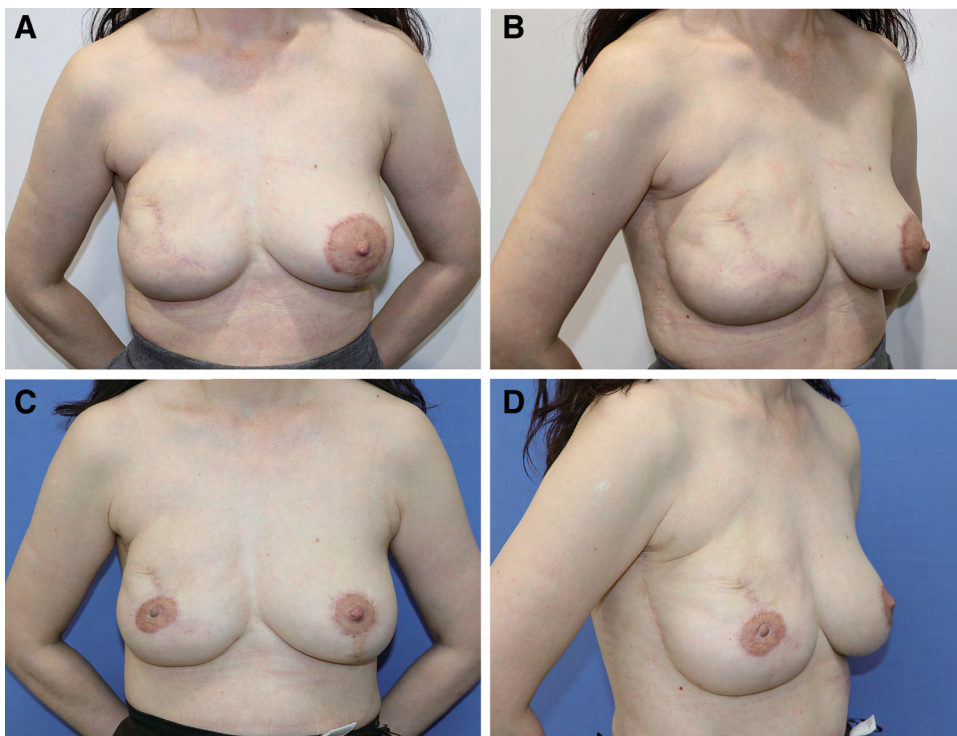


Fig. 3. A 51-year-old patient who underwent 2-stage, delayed reconstruction with a breast implant after mastectomy for right breast cancer. A, B, Preoperative photographs. IMF ptosis and loss of definition were noted. C, D, Photographs taken 11 months after corrective surgery.

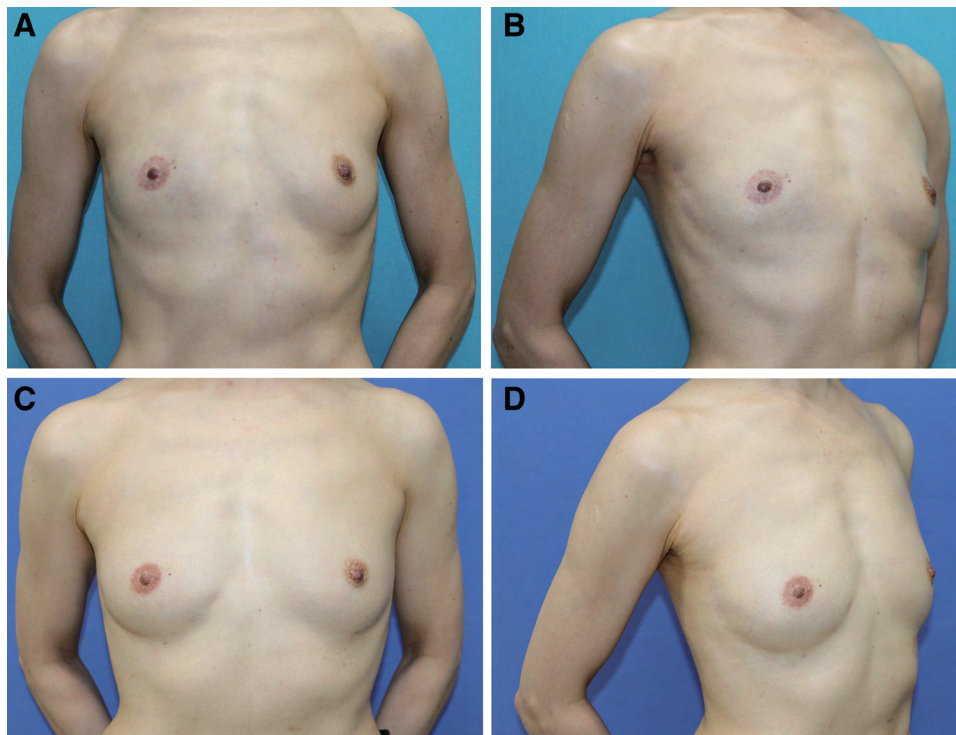


Fig. 4. A 50-year-old patient who underwent 2 sessions of fat grafting after skin-sparing mastectomy for right breast cancer. A, B, Preoperative photographs. Loss of definition of the IMF was noted. C, D, Photographs taken 9 months after IMF corrective surgery and the last fat grafting session.

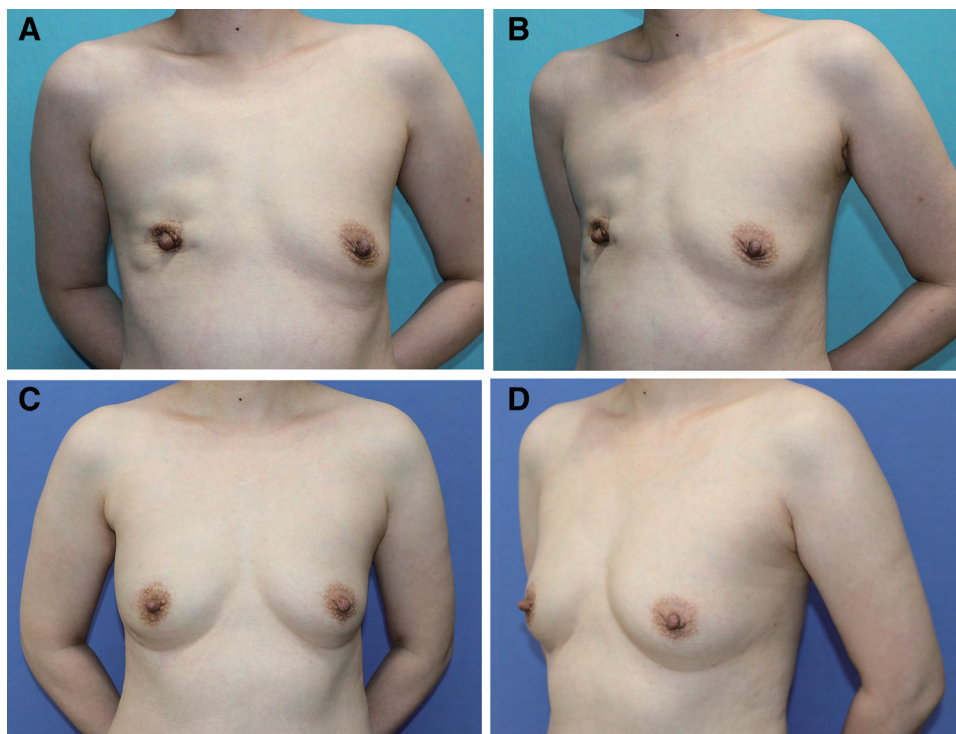


Fig. 5. A 44-year-old patient planned to undergo delayed reconstruction with a latissimus dorsi musculocutaneous flap after nipple-sparing mastectomy for right breast cancer. A, B, Preoperative photographs. The patient complained of uncomfortable bra fit given the poor definition of the contralateral IMF, and thus recreation of the contralateral IMF at the same time as delayed reconstruction was planned. C, D, The IMF was symmetrical at 15 months postoperatively.

Moreover, in cases of breast reconstruction using fat grafts or IMF correction of the contralateral breast, making skin incisions can be difficult. Our external approach, which is a modified version of the drawstring method,¹¹ allows for the recreation of a scarless, smooth, and well-defined IMF. The major difference between the original method and our method is that the original method is essentially an internal approach, whereas ours is an external approach. Although Terao et al¹¹ also presented 1 case (contralateral breast correction) with an external approach, they fixed the suture to the deep tissue at the lateral end of the IMF through the small incision and penetrated the dermis medially. We believe that fixation at the medial end of the IMF provide greater breast mobility. By adjusting the depth of the barbed suture, IMF definition can also be fine-tuned. Since the method can be carried out under local anesthesia, it offers the benefits of lower medical costs and physical burden on patients.

Visconti et al¹² recently reported that embedding 2 barbed sutures subcutaneously in fat grafting breast augmentation led to significantly better postoperative breast shape. While the procedure has the benefits of avoiding scars and uses absorbable sutures, it might not be applicable for IMF correction after breast reconstruction. Specifically, because fat grafting breast augmentation imparts dramatic changes (eg, edema) to the IMF and the breast itself, internal scars can easily form in the IMF. Such major changes are not observed with minor corrective surgery of the reconstructed breast, but the IMF may revert back to its original form to some extent after suture absorption. Indeed, in our past experiences with absorbable sutures, the IMF began reverting back to its original form in some cases after suture absorption. The new method uses nonabsorbable sutures, and thus while slack in the suture is possible for up to three months postoperatively, subsequent changes are minimal. Although the follow-up periods in some cases are not enough, subsequent changes are minimal in most cases. Although leaving the barbed suture in the body could be considered a drawback, fixation by the barbed suture is limited to the medial side of the breast and thus is of less hindrance. None of the patients of this study complained of an awkward or unnatural feeling after undergoing the procedure.

As with the original method, the present method has some limitations. First, unlike dermal sutures, the barbed suture is not spiral-shaped and is embedded subcutaneously in a linear fashion. Thus, the suture does not strongly grip the subcutaneous tissue, and when forcefully pulled, slack in the suture may result. In cases of high suture tension, wearing supporting underwear for about 3 months to hold the IMF in position is important. Equally important is identifying patients indicated for the method. In this study, slack in the suture was observed in 2 patients of the DIEP group with relatively heavy flap weight and in 1 patient in the breast implant group. Patients indicated for this method are likely those who can easily raise their breasts by hand, that is, fat grafting autologous reconstruction cases and flap surgery cases, as well as patients with small breast size. On the other hand, cases of reconstruction with textured breast implants which allow for little movement are less likely to be indicated for the method, whereas cases with smooth

implants might be an indication for the method. Similarly, care should be taken when applying the method to patients with large breast size (eg, >400 g).

CONCLUSIONS

While careful consideration of patients indicated for the new method is required, the strength of this method is that it allows for scarless IMF recreation under local anesthesia. The method is particularly suited for those who require secondary IMF correction following breast reconstruction and for those who desire IMF recreation for the contralateral breast.

Koichi Tomita, MD, PhD

Department of Plastic and Reconstructive Surgery
Graduate School of Medicine
Osaka University
2-2 Yamadaoka Suita
Osaka 5650871, Japan
E-mail: ktomita9@hotmail.co.jp

ACKNOWLEDGMENT

We declare that all procedures conformed to the Declaration of Helsinki, and appropriate informed consent was obtained from all patients.

REFERENCES

1. Kraft CT, Rendon JL, Koutz CA, et al. Inframammary fold reconstruction in the previously reconstructed breast: a comprehensive review. *Plast Reconstr Surg*. 2019;143:1019–1029.
2. Pennisi VR. Making a definite inframammary fold under a reconstructed breast. *Plast Reconstr Surg*. 1977;60:523–525.
3. Ryan JJ. A lower thoracic advancement flap in breast reconstruction after mastectomy. *Plast Reconstr Surg*. 1982;70:153–160.
4. Bogetti P, Cravero L, Spagnoli G, et al. Aesthetic role of the surgically rebuilt inframammary fold for implant-based breast reconstruction after mastectomy. *J Plast Reconstr Aesthet Surg*. 2007;60:1225–1232.
5. Handel N, Jensen JA. An improved technique for creation of the inframammary fold in silicone implant breast reconstruction. *Plast Reconstr Surg*. 1992;89:558–562.
6. Nava M, Quattrone P, Riggio E. Focus on the breast fascial system: a new approach for inframammary fold reconstruction. *Plast Reconstr Surg*. 1998;102:1034–1045.
7. Versaci AD. A method of reconstructing a pendulous breast utilizing the tissue expander. *Plast Reconstr Surg*. 1987;80:387–395.
8. Otani N, Tomita K, Taminato M, et al. Efficacy of STRATAFIX in inframammary fold recreation in autologous breast reconstruction. *Plast Reconstr Surg Glob Open*. 2018;6:e1702.
9. Ismagilov A, Vanesyan A, Kamaletdinov I. Small refinements in breast reconstruction: a technique for inframammary fold creation. *Gland Surg*. 2017;6:132–140.
10. Hirsch EM, Seth AK, Fine NA. Reconstruction of the inframammary fold using barbed suture. *Ann Plast Surg*. 2014;72:388–390.
11. Terao Y, Taniguchi K, Tomita S. A new method for inframammary fold recreation using a barbed suture. *Aesthetic Plast Surg*. 2015;39:379–385.
12. Visconti G, Salgarello M. Dual-anchor cog threads in fat grafting breast augmentation: a novel scarless method for defining breast footprint and enhancing shape. *Plast Reconstr Surg*. 2019;143:1039–1049.
13. Tomita K, Yano K, Nishibayashi A, et al. Aesthetic outcomes of inframammary fold recreation in two-stage, implant-based, breast reconstruction. *Springerplus*. 2016;5:1656.