

Immediate Soft-Tissue Reconstruction for Chronic Infected Tibia Nonunions Treated with an Ilizarov Frame

Kevin T. Jubbal, MD*
 Dmitry Zavlin, MD†
 Andres F. Doval, MD†
 Steven M. Cherney, MD‡
 Mark R. Brinker, MD§
 Tue A. Dinh, MD†
 Anthony Echo, MD†

Summary: There are multiple options available for the management of large tibial defects. The Ilizarov frame is one of the most widely used techniques due to the physiological bone growth and the symmetrical distribution of axial forces permitting adequate bone distribution. However, disadvantages still remain including obtaining additional soft-tissue access for defect coverage. We present our experience with soft-tissue reconstruction for chronic infected tibial nonunions using free tissue transfers simultaneously with Ilizarov device placement. A retrospective review was performed from 2014 to 2016 of patients presenting with a chronically infected tibia nonunion and treated by our senior orthopedic and plastic surgeons. Demographic data, comorbidities, intraoperative details and postoperative outcomes were collected. A total of 6 patients were identified with a mean age of 46.2 ± 11.6 years. Complete flap survival and resolved active infection were achieved in 5 of our patients, 4 demonstrated body union on imaging, and all of them reached complete ambulence. Flap revisions with allografting for partial flap loss were performed in 1 patient. Preoperative planning is critical for immediate lower extremity reconstruction in the setting of an Ilizarov frame. From our institutional experience, free tissue transfer can safely be placed after frame placement. (*Plast Reconstr Surg Glob Open* 2019;7:e2180; doi: 10.1097/GOX.0000000000002180; Published online 13 March 2019.)

INTRODUCTION

Exposed fractures of the tibia are common. The rate of occurrence is approximately 4%, which is equivalent to 250,000 fractures/y in the United States.¹ Complications often occur and are influenced by the severity of soft-tissue damage and degree of fracture site contamination. Rates for infections range around 5%–16% and for nonunions between 5% and 30%.²

A number of surgical techniques have been devised to manage fracture injuries of large tibial defects. One

of the most widely used approach is the use of external fixation with gradual limb lengthening by distraction osteogenesis, also known as the Ilizarov technique.^{2–4} This technique allows early weight bearing, decreasing the risk of additional surgery for delayed unions, and is effective in reconstruction of fractures with significant osseous deficit.^{5,6} Despite the well-known advantages of this technique, it traditionally has not allowed appropriate immediate soft-tissue coverage for large defects unless acute shortening is performed.⁵

The goal of this study is to describe our experience with soft-tissue reconstruction for limb salvage of chronically infected tibia nonunions in conjunction with the Ilizarov technique.

METHODS

Patient Selection

We performed a retrospective chart review of patients presenting with a chronically infected tibia nonunion between 2014 and 2016. Patients were included if they were treated with the Ilizarov technique, and if they required immediate soft-tissue reconstruction with free tissue transfer.

Disclosure: The authors have no financial interest to declare in relation to the content of this article.

From the *Department of Plastic and Reconstructive Surgery, Loma Linda University Medical Center, Loma Linda, Calif.; †Institute of Reconstructive Surgery, Houston Methodist Hospital, Weill Cornell Medicine, Houston, Tex.; ‡Department of Orthopedic Surgery, University of Arkansas for Medical Science, Little Rock, Ark.; and §Fondren Orthopedic Group L.L.P., Texas Orthopedic Hospital, Houston, Tex.

Received for publication October 12, 2018; accepted October 22, 2018.

Copyright © 2019 The Authors. Published by Wolters Kluwer Health, Inc. on behalf of The American Society of Plastic Surgeons. This is an open-access article distributed under the terms of the Creative Commons Attribution-Non Commercial-No Derivatives License 4.0 (CCBY-NC-ND), where it is permissible to download and share the work provided it is properly cited. The work cannot be changed in any way or used commercially without permission from the journal.

DOI: 10.1097/GOX.0000000000002180

Table 1. Demographics and Clinical Characteristics

| Variable (N=6) | Value |
|--|------------|
| Age, y (mean ± SD) | 46.2±11.6 |
| Gender | |
| Male | 4 (66.7%) |
| Female | 2 (33.3%) |
| Body mass index, kg/m ² (mean ± SD) | 26.7±5.3 |
| Smoking | |
| No | 5 (83.3%) |
| Former | 0 (0.0%) |
| Active | 1 (16.7%) |
| Diabetes | 2 (33.3%) |
| Hypertension | 1 (16.7%) |
| Primary orthopedic diagnosis | |
| Open distal tibia fracture and nonunion | 1 (16.7%) |
| Open pilon fracture and nonunion | 3 (50.0%) |
| Open tibial shaft fracture and nonunion | 2 (33.3%) |
| Chronic infection | 6 (100.0%) |

For each case identified, demographic data, comorbidities, primary diagnosis, intraoperative details, and postoperative outcomes were collected.

Statistics and Ethics

IBM SPSS software (Version 25.0. Armonk, NY, IBM Corp.) was used for all descriptive and statistical analysis.

RESULTS

A total of 6 patients met the inclusion criteria with an average age of 46.2±11.6 years and average body mass index of 26.7±5.3. Pertinent history includes: history of smoking (1 patient), hypertension (1 patient), and diabetes mellitus (2 patients). The most common primary indication for surgery was an open Pilon fracture with nonunion (Table 1).

All patients were exposed to serial debridements 7.3±0.8 days before Ilizarov frame placement followed by direct free tissue reconstruction. Flap types were free rectus and gracilis muscle flaps (Table 2).

In regards complications and primary outcomes within the follow-up time (21.3±4.1 months), 2 patients experienced docking site nonunions that required operative intervention by the orthopedic service and one partial flap loss that was addressed by the plastic surgeon. Moreover, 5 patients demonstrate full flap survival, complete soft-tissue closure, and no ongoing infection. Four showed full bone healing based on radiographic evaluation and all patients demonstrated ambulation. None of the 6 patients required amputation (Table 3).

DISCUSSION

This case series demonstrates our positive experience of the optimization of soft-tissue reconstruction of the lower limb by performing free tissue transfer after the Ilizarov frame placement for limb salvage.

Table 2. Primary Surgical Management

| Variable (N=6) | Value |
|-------------------------------------|------------|
| Flap type | |
| Free rectus muscle flap | 4 (66.7%) |
| Free gracilis muscle flap | 2 (33.3%) |
| Cultured organisms | |
| Gram-positive bacteria | 6 (100.0%) |
| <i>Staphylococcus</i> species | 5 (83.3%) |
| Methicillin-resistant | 0 (0.0%) |
| <i>Staphylococcus aureus</i> | |
| <i>Enterococcus faecalis</i> | 1 (16.7%) |
| <i>Streptococcus</i> species | 1 (16.7%) |
| Gram-negative bacteria | 4 (66.7%) |
| <i>Pseudomonas aeruginosa</i> | 3 (50.0%) |
| <i>Enterobacter cloacae</i> | 1 (16.7%) |
| <i>Stenotrophomonas maltophilia</i> | 1 (16.7%) |
| Other | 1 (16.7%) |
| <i>Candida parapsilosis</i> | 1 (16.7%) |
| Culture negative | 0 (0.0%) |

Table 3. Postoperative Outcomes

| Variable (N=6) | Value |
|---|-----------------|
| Complications | |
| Docking site nonunion | 2 (33.3%) |
| Tissue invagination | 0 (0.0%) |
| Partial flap loss | 1 (16.7%) |
| Wire drainage requiring intravenous antibiotics | 0 (0.0%) |
| None | 3 (50.0%) |
| Full soft-tissue closure | 5 (83.3%) |
| Flap survival | 5 (83.3%) |
| Partial flap loss | 1 (16.7%) |
| Bone healing on radiographic imaging | 4 (66.7%) |
| Amputation | 0 (0.0%) |
| Satisfactory functionality (walking) | 6 (100.0%) |
| Follow-up time, mo (mean ± SD, median) | 21.3±4.1 (19.7) |

It has been suggested that the Ilizarov frame must be placed after flap transfer when it is required, given that the frame used in conjunction with free tissue transfer restricts space and view, increases risk associated with the procedure, and adds to the difficulty of performing microvascular anastomoses.^{7,8} However, by performing the flap after the frame has been placed, the risk of inadvertent injury to the flap is removed.⁹ Here, we present our surgical tips for free tissue transfer in the setting of an Ilizarov device.

Free Flap Selection

Muscle flaps are ideal for placement through the Ilizarov frame, as they allow for rapid elevation, predictable anatomy. The muscle flap can be partially split in either parallel (3–4 cm) or perpendicular (1 cm) directions to the muscle fibers in small increments. This allows flexibility around olive wires and pins. The flap choices for small-to-moderate-sized wounds are the rectus abdominis muscle flap and the gracilis muscle flap.

Long Microsurgery Instruments

The use of long microsurgical instruments (18 cm) is critical when operating through the frame, because the shorter instruments will not be able to reach the anastomosis.

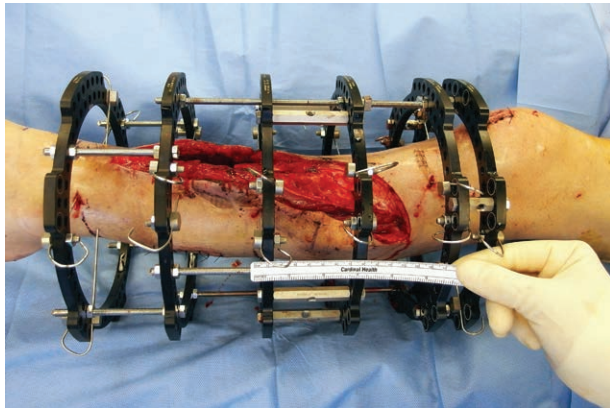


Fig. 1. Space between the middle rings of the Ilizarov frame.

High Power Loupes

Loupes at magnification of 3.5× or 4.0× is necessary for the surgery because a microscope will be able to position correctly to prevent poor posture or the instruments hitting the bottom of the microscope.

Limited Help

The surgeon should feel comfortable in preparing the vessels and performing the anastomosis without an assistant because the frame will prevent a second set of hands into the operating field.

Vessel Selection and Access

By being present during the initial surgery debridement, the plastic surgeon can determine which vessels will be optimal for the eventual free tissue transfer. Also, adequate exposure of the vessels should be performed before the frame being placed. Vessels should be exposed between the 2 rings with the largest distance separating them (ideally >10 cm) as this will usually be the middle 2 rings stabilizing the mid-shaft of the tibia (Fig. 1).

Anastomosis Type

A continuous running suture on the anterior and posterior sides is preferred because this limits the maneuvers required through the frame by limiting the number of knots needed per anastomosis. However, this is a secondary priority when there is only one major vessel, in which case an end-to-side anastomosis should be performed to preserve perfusion to the foot.

For the venous anastomosis, we use a venous coupler device half size smaller than the smaller vessel to be anastomosed. The surgeon holds both the coupler device and

the pusher while performing the anastomosis independently.

CONCLUSIONS

Performing a free tissue transfer after placement of an Ilizarov frame for bone transport can be challenging, but with standardization of the approach using described tips, one can achieve successful limb salvage with limited assistance.

Anthony Echo, MD

Institute for Reconstructive Surgery
Houston Methodist Hospital
6560 Fannin Street
Scurlock Tower, Suite 2200
Houston, TX 77030
E-mail: aecho@houstonmethodist.org

ACKNOWLEDGMENTS

The work described in this article was approved by our institutional review board (Protocol number: 00011704).

Statement of Conformity: The authors adhere to the Declaration of Helsinki at all times.

REFERENCES

1. Jaña Neto FC, de Paula Canal M, Alves BAF, et al. Analysis of the characteristics of patients with open tibial fractures of Gustilo and Anderson type III. *Rev Bras Ortop (English Ed)*. 2016;51:143–149. doi:10.1016/j.rboe.2016.01.002
2. Fürmetz J, Soo C, Behrendt W, et al. Bone transport for limb reconstruction following severe tibial fractures. *Orthop Rev (Pavia)*. 2016;8:6384.
3. Kumar G, Narayan B. The tension-stress effect on the genesis and growth of tissues. Part I. The influence of stability of fixation and soft-tissue preservation. In: *Classic Papers in Orthopaedics*. 2014. doi:10.1007/978-1-4471-5451-8_136. Editor, Paul A. Banaszkiwicz and Deiry F. Kader. Springer: Newcastle, UK.
4. Ilizarov GA. The tension-stress effect on the genesis and growth of tissues. Part II. *Clin Orthopaedics Relat Research*. 1989;263–285. doi:10.1007/978-1-4471-5451-8_137
5. Lowenberg DW, Feibel RJ, Louie KW, et al. Combined muscle flap and Ilizarov reconstruction for bone and soft tissue defects. *Clin Orthop Relat Res*. 1996;37–51.
6. Öztürkmen Y, Karamehmetoğlu M, Karadeniz H, et al. Acute treatment of segmental tibial fractures with the Ilizarov method. *Injury*. 2009;40:321–326. doi:10.1016/j.injury.2008.07.013
7. Paley D, Maar DC. Ilizarov bone transport treatment for tibial defects. *J Orthop Trauma*. 2000;14:76–85.
8. Kim KN, Hong JP, Park SW, et al. Overcoming the obstacles of the Ilizarov device in extremity reconstruction: usefulness of the perforator as the recipient vessel. *J Reconstr Microsurg*. 2015;1:420–425. doi:10.1055/s-0035-1548549
9. Repo JP, Barner-Rasmussen I, Roine RP, et al. Treatment of compound tibia fracture with microvascular latissimus dorsi flap and the Ilizarov technique: a cross-sectional study of long-term outcomes. *J Plast Reconstr Aesthet Surg*. 2016;69:524–532.