

Reconstruction of Lumbar Spinal Defects: Case Series, Literature Review, and Treatment Algorithm

Lauren T. Daly, MD*
 Ricardo Ortiz, BSc†
 John H. Shin, MD‡
 Branko Bojovic, MD†
 Kyle R. Eberlin, MD†

Background: Lumbar spinal defects present a distinct challenge for the reconstructive surgeon and are often complicated by previous spinal surgery, the presence of hardware, and prior radiation. There are a variety of reconstructive options described but no clear treatment algorithm for these challenging defects.

Methods: A literature search was performed to review the described treatment options for lumbar spinal soft-tissue defects. Treatments for myelomeningocele or pressure ulcers were excluded. In addition, a retrospective case review was performed for patients with lumbar defects treated with pedicled superior gluteal artery perforator (SGAP) flap reconstruction.

Results: A literature review revealed 2,022 articles pertaining to lumbar defect reconstruction, of which 56 met inclusion criteria. These articles described 13 individual reconstructive techniques for this anatomic area. The most commonly described techniques were evaluated and a treatment algorithm designed based on patient and wound characteristics. The clinical course of 5 patients with radiated lumbar spinal defects treated with SGAP flaps is presented.

Conclusions: There are many treatment options for lumbar spinal defects and treatment should be tailored to the patient and the characteristics of the defect. For large or radiated lumbar wounds, the pedicled SGAP flap is an excellent reconstructive choice, as it has reliable anatomy that is outside the zone of injury, adequate bulk, and minimal donor-site deficits. (*Plast Reconstr Surg Glob Open* 2019; 7:e2089; doi: 10.1097/GOX.0000000000002089; Published online 11 January 2019.)

INTRODUCTION

Midline lumbar spinal defects represent a unique challenge for the reconstructive surgeon. The local soft tissues of the lumbar spine are densely adherent, subject to considerable motion in the sagittal plane, and have a paucity of nearby muscle to serve for defect coverage.¹ Unlike the sacrum, thoracic, and cervical spine, the lumbar spine presents more significant reconstructive challenges for soft-tissue coverage.

These defects have myriad etiologies, but are often the result of spinal deformity corrective surgery, tumor resection, or pressure necrosis.² Lumbar wounds related to

extirpative surgery can be especially challenging as these patients often have a history of radiation to the lumbar region, exposed spinal hardware or spinal cord, cerebrospinal fluid leak, or infection. Reconstruction following these extirpative surgeries requires obliteration of dead space and provision of healthy tissue for the cutaneous defect.

Further complicating reconstructive efforts, previous spinal surgery and radiation can affect nearby vessels rendering this area unreliable for coverage with traditional pedicled flaps. A variety of reconstructive options have been previously described without a clear algorithm for intervention. In this article, we review the existing literature on lumbar defect reconstruction and create a treatment algorithm based on wound and patient characteristics. In addition, we discuss the specific use of pedicled superior gluteal artery perforator (SGAP) flaps for reconstruction of large lumbar wounds.

METHODS

Literature Search

A literature search was conducted of PubMed and Scopus databases using the search strategy: [reconstructive

Disclosure: Dr. Eberlin is a consultant for AxoGen and Integra. Dr. Shin is a consultant for Medtronic and Stryker. The Article Processing Charge was paid for by the authors.

From the *Department of Surgery, Division of Plastic and Reconstructive Surgery, University of Massachusetts, Worcester, Mass.; †Department of Surgery, Division of Plastic and Reconstructive Surgery, Massachusetts General Hospital, Boston, Mass.; and ‡Department of Neurosurgery, Massachusetts General Hospital, Boston, Mass.

Received for publication September 27, 2018; accepted November 6, 2018.

Copyright © 2019 The Authors. Published by Wolters Kluwer Health, Inc. on behalf of The American Society of Plastic Surgeons. This is an open-access article distributed under the terms of the Creative Commons Attribution-Non Commercial-No Derivatives License 4.0 (CCBY-NC-ND), where it is permissible to download and share the work provided it is properly cited. The work cannot be changed in any way or used commercially without permission from the journal.
 DOI: 10.1097/GOX.0000000000002089

Table 1. Patient Characteristics and Complications

Case	Age	Sex	Pathology	Defect Level	Time to Recon. (d)	Follow-up (wk)	Spinal Hardware	Bone Graft	Radiation	DM	Smoker	Defect Size (cm)	Complications
1	63	M	Chordoma	L2-L4	295	107	Yes	Yes	Yes	No	No	21×7	None
2	68	F	Scoliosis	L2-L3	27	7	Yes	Yes	No	No	Yes	24×9	Venous congestion requiring flap delay
3	70	M	Chordoma	L2-L4	30	13	Yes	Yes	Yes	No	Yes	24×9	Infection requiring I&D
4	34	M	Chordoma	L2-L4	365	110	Yes	Yes	Yes	No	Yes	24×8	Infection requiring I&D
5	53	M	Chordoma	L5-S4	8	18	No	No	Yes	No	No	20×9	Infection requiring I&D

DM, diabetes mellitus; I&D, irrigation and debridement; Recon., reconstruction.

surgical procedure (MeSH Terms)] AND lumbar, yielding articles from 1948 to January 2018. After removal of duplicate entries, titles of the articles and then abstracts were reviewed to assess for inclusion. The bibliographies of included articles were then reviewed for other relevant articles. Prospective studies, retrospective reviews, case series, and case reports in the English language were included. Exclusion criteria included purely anatomic studies, non-human studies, basic science or histology studies, articles that described myelomeningocele alone, or articles that described pressure wounds alone. Data gathered from articles included year of publication, level of evidence, number of patients treated, inclusion of wounds with prior radiation, and method of lumbar reconstruction.

Patient Selection

A review was conducted of a prospectively maintained institutional surgical database from 2014 to 2018 (Massachusetts General Hospital IRB# 2018P000815). All

patients with lumbar wounds, defined as soft-tissue defects at levels L1 to L5, and treated with pedicled SGAP reconstruction were included in our case series (Table 1). We then performed a retrospective chart review on each patient to collect data on the indication for reconstruction, size and location of the defect, and outcomes of the reconstruction.

RESULTS

Literature Search

A literature review revealed 2,022 articles pertaining to lumbar defect reconstruction, of which 56 met the stated inclusion criteria. The articles dated from 1987 to 2017, with 11 articles describing more than one technique. The average level of evidence was 4.29, with 4 level 3 studies, 32 level 4 studies, and 20 level 5 studies. Multiple options for reconstruction were described including free style perforator flap,³⁻⁹ lumbar artery per-

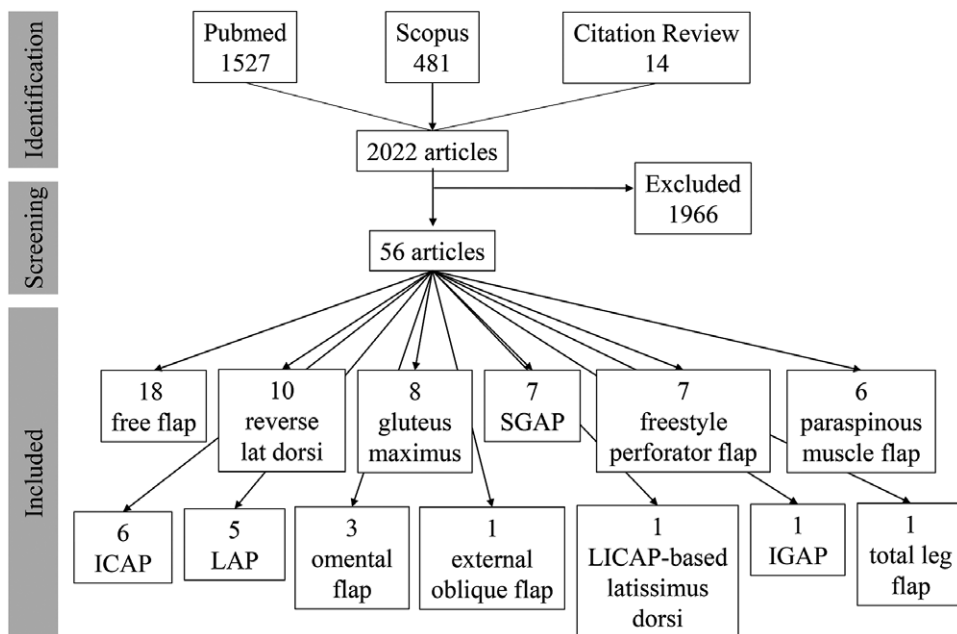


Fig. 1. Results of literature search for lumbar wound reconstruction. Fifty-six articles discussing 13 reconstructive techniques were reviewed, with free flap and reverse latissimus dorsi flap reconstruction being the most commonly discussed techniques. Eleven studies discussed more than one reconstructive technique. ICAP, intercostal artery perforator flap; IGAP, inferior gluteal artery perforator flap; LICAP, lateral intercostal artery perforator.

forator (LAP) flap,^{6,8,10–12} paraspinous muscle flap,^{2,13–17} SGAP,^{10,14,18–22} inferior gluteal artery perforator,¹⁹ intercostal artery perforator flap,^{8,10,11,20,23,24} gluteus maximus musculocutaneous flap,^{1,2,13,25–29} reverse latissimus dorsi flap,^{2,7,13,27,30–35} lateral intercostal artery perforator–based latissimus dorsi flap,³⁶ external oblique musculocutaneous pedicled flap,³⁷ pedicled omental flap,^{38–40} free flap,^{7,13,14,41–55} and total leg flap.⁵⁶ The most frequently described method of lumbar wound reconstruction was free flap with 18 articles, followed by reverse latissimus dorsi flap reconstruction with 10 articles (Fig. 1). The most infrequently described methods were inferior gluteal artery perforator, lateral intercostal artery perforator–based latissimus dorsi flap, total leg flap, and external oblique musculocutaneous pedicled flap with 1 article each. Twenty-five of the 56 articles mentioned at least 1 patient with lumbar radiation. Among studies including patients with lumbar radiation, free flap remained the most commonly described reconstructive technique with 8 articles, followed by reverse latissimus dorsi flap with 6 articles, and paraspinous muscle flap with 5 articles.

Case Reports

Case 1

A 63-year-old man with history of L3-L4 chordoma involving the lumbosacral soft tissues presented with a nonhealing infected lumbar wound after undergoing radiation, en bloc resection of the chordoma with anterior spinal instrumentation of L1-L5, posterior spinal

instrumentation of L1-S1 with sacral-iliac fusion, placement of femoral ring bone allografts and primary dural repair. Despite 2 washouts and hardware replacement by the orthopedic oncology team, the nonhealing infected wound persisted and so reconstruction with an SGAP flap was planned. At the time of reconstruction, the defect measured 28 by 6 cm with exposed hardware and significant dead space between skin and spine. Primary closure of the cephalic and caudal aspects of the wound resulted in an open wound measuring 10 by 4 cm. Following SGAP reconstruction, the patient went on to heal with no complications at 24-month follow-up.

Case 2

A 68-year-old ambulatory woman with spinal deformity and multiple prior spinal surgeries, most recently a L2-L3 revision of pseudarthrosis and replacement of broken rods, presented with a postoperative cerebrospinal fluid leak. Cultures were positive for pseudomonas and so she returned to the OR for repeated I&D, paraspinous muscle flap closure of the superior 2/3 of the lumbar wound, and negative pressure wound therapy dressing placement to the lower 1/3. She unfortunately developed a recurrent cerebrospinal fluid leak, and returned to the operating room where a SGAP pedicled perforator flap was performed for reconstruction. After inset of the flap, venous congestion was noted so the flap was replaced and delayed for 1 week. After flap reinsert, the patient went on to heal without complication after 7-week follow-up.

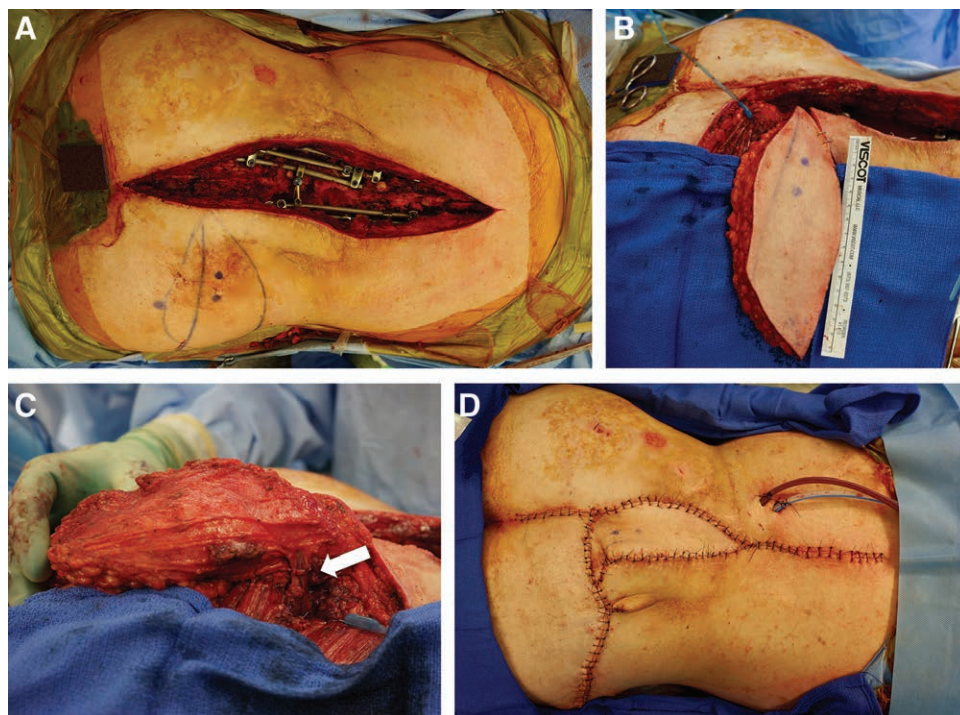


Fig. 2. Intraoperative photographs of case 4 demonstrating patient in prone position with head to right of each image. A, Large 24 × 8 cm lumbar defect in an irradiated field with exposed posterior instrumentation and bone allograft. B, Elevated SGAP flap illustrating adequate volume of adipofasciocutaneous tissue. C, Arrow indicates SGAP pedicle outside the zone of injury and radiation. D, Flap inset and primary closure resulting in tension-free closure.

Case 3

A 70-year-old ambulatory man with L3 chordoma complicated by significant soft tissue involvement and prior radiation developed an infected nonhealing wound with exposed spinal cord and hardware after undergoing an en bloc spondylectomy of L2-L4 with anterior and posterior spinal instrumentation and anterior spinal reconstruction with a vascularized fibular flap. After prolonged course of antibiotics and 4 operative wash-outs, the patient underwent SGAP flap reconstruction. He developed a fluid collection requiring drain placement, and subsequently went on to heal this lumbar defect at 3-month follow-up.

Case 4

A 34-year-old ambulatory man with L4 chordoma status post L4 corpectomy, L2-S1 posterior fusion and radiation who went on to develop recurrent chordoma requiring L2-L3 spondylectomy with anterior and posterior fusion with femoral ring allograft placement presented with hardware failure requiring hardware revision (Fig. 2). Plastic surgery was consulted and performed SGAP flap reconstruction of the lumbar spinal defect. His postoperative course was complicated by soft-tissue infection requiring 2 operative wash-outs before ultimate healing. Unfortunately, his course was later complicated by recurrent chordoma and pulmonary metastasis; however, his wound remained healed at his most recent clinic visit 25 months after his reconstruction.

Case 5

A 53-year-old ambulatory man with sacrococcygeal chordoma extending to the perirectal and lumbar subcutaneous tissues and a history of neoadjuvant radiation presented for staged resection and reconstruction including anterior sacral osteotomies, ureteral stents, and low anterior resection with ileostomy, with subsequent en bloc sacrectomy with sparing of the gluteal vessels, and anal resection. The plastic surgery team was consulted preoperatively, and a left SGAP flap was planned for coverage of the lumbosacral wound. Following debridement 6 days prior, an SGAP flap was used to cover the lumbosacral wound measuring 10×15×8cm. Postoperatively, his course was complicated by a wound infection, for which he underwent 2 debridements and treatment with IV antibiotics. He went on to heal without further complications at 4-month follow-up.

DISCUSSION

The lumbar spine is a challenging area for soft-tissue coverage, with a complication rate of 26–48% following reconstructive surgery.^{13,17} Further limiting reconstructive options are the presence of prior radiation or need for future radiation, spinal instrumentation, and wide local oncologic resections, which often affect the local and regional options for coverage.¹³ Multiple techniques have been described for lumbar spinal reconstruction, ranging from local perforator-based fasciocutaneous flap coverage to complex free flap reconstructions with vein grafts (Fig. 3).^{10,51} Although there are insufficient number of published studies to conduct a comprehensive, compara-

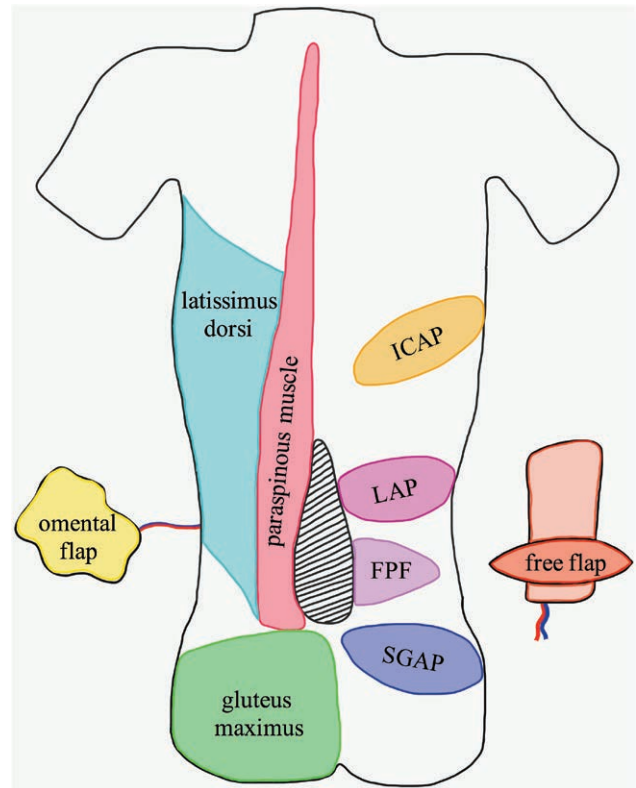


Fig. 3. Of the 13 reconstructive techniques described in the literature, the 9 techniques demonstrated here were described by more than one study. Hatched area represents lumbar wound. FPF, free style perforator flap; ICAP, intercostal artery perforator flap.

tive meta-analysis between described treatment options, these techniques can be placed into a treatment algorithm based on the characteristics of the patient and the lumbar defect to facilitate surgical planning (Fig. 4).

The ideal closure for lumbar spinal wounds should provide reliable coverage for the spinal cord and any existing hardware, while minimizing donor-site defects and functional morbidity. In considering a treatment algorithm, the surgeon must account for the size of the defect, the presence of radiated tissue, and the patient's ambulatory status when considering closure options. It is rarely possible to close these wounds primarily without tension.

When available and sufficient, the paraspinus muscles may provide a reliable local reconstructive flap option for lumbar defects of many sizes. Although discussed less in the published literature, the paraspinus muscle flap is the most commonly utilized muscle flap in many large case series describing different techniques for lumbar spinal defects.^{2,13,14} The paraspinus muscle flap has a reliable blood supply from the lumbar arteries, has longitudinal anatomy that compliments the geometry of most spinal wounds, and spares the need for a second donor-site incision.¹⁷ Unfortunately, the paraspinus musculature and/or lumbar arteries may be scarred or absent in many acquired lumbar defects making other reconstructive options necessary.

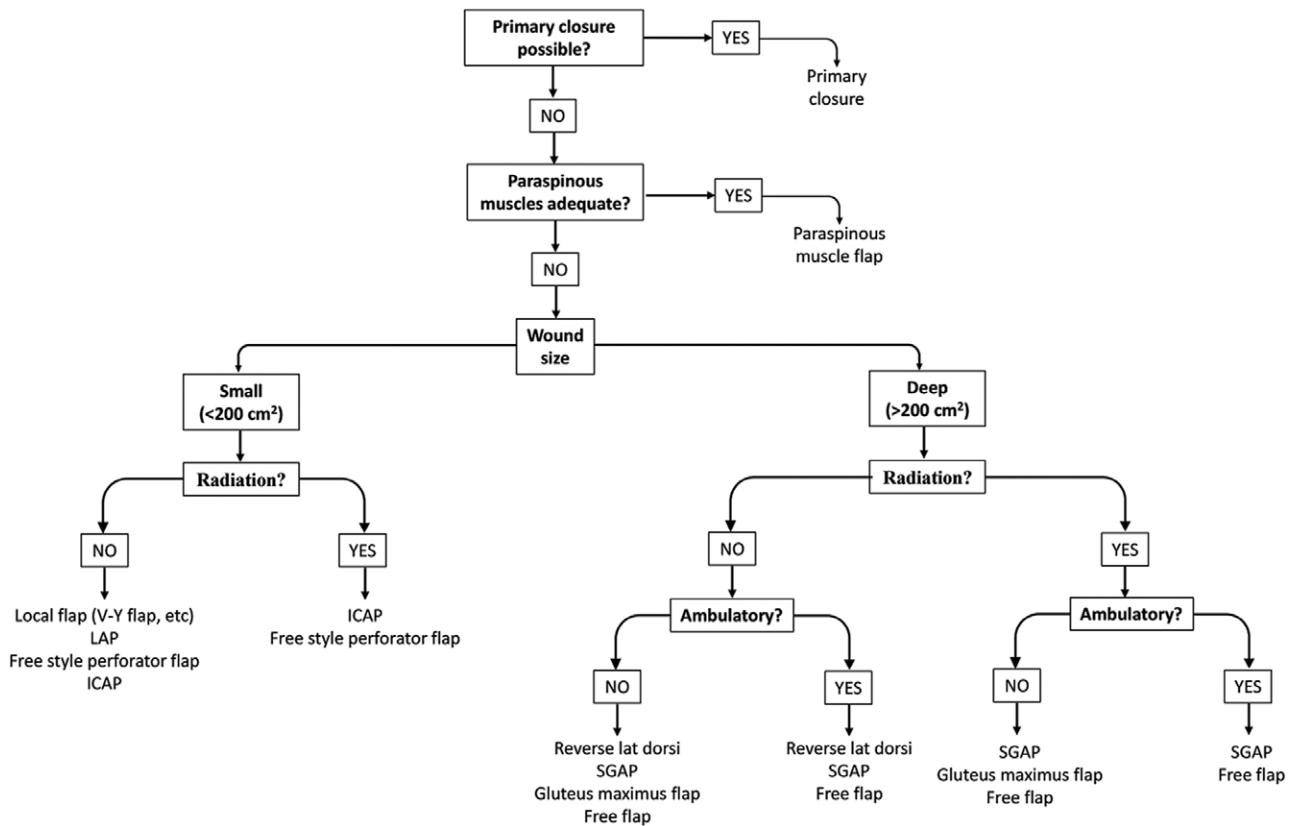


Fig. 4. Lumbar defect reconstruction algorithm. glut max, gluteus maximus flap; ICAP, intercostal artery perforator flap; Lat dorsi, reverse latissimus dorsi flap.

Smaller wounds in nonradiated patients may be addressed with local perforator flaps or local/regional fasciocutaneous flaps. A history of lumbar radiation can compromise the lumbar arteries, and reconstructive options based on the angiosome of the lumbar artery (such as the lumbar artery perforator flap and reverse latissimus dorsi flap) should be avoided in these circumstances. Larger lumbar wounds require a greater volume of tissue to obliterate dead space. Large lumbar spinal wounds have historically been defined in prior publications as having a size $>200\text{ cm}^2$, although this definition is not based on clinical data.⁵⁷ Closure of these larger lumbar spinal wounds can be achieved by utilizing bulkier pedicled fasciocutaneous flaps, pedicled musculocutaneous flaps, or free flaps.

Historically, muscle and musculocutaneous flaps have been the preferred method of reconstruction for wounds with concern for infection or impaired bone healing. The gluteus maximus muscle can be utilized as a pedicled flap for reconstruction of large lumbar wounds; however, this can cause functional limitations in ambulatory patients and should be avoided in this population.⁵⁸ This dogma that muscle flaps provides superior wound coverage as compared with fasciocutaneous flaps has been challenged recently in many parts of the body and has perhaps been best studied in the lower extremity.^{59,60} Although there are no studies directly comparing reconstructive options in the lumbar spine, evidence shows that fasciocutaneous flaps

are similar to muscle flaps in flap-related complications, bony nonunion, osteomyelitis, and functional outcomes in lower extremity wounds.^{59,60} Fasciocutaneous flaps are also associated with fewer functional donor-site defects, as they do not require harvest of muscle required for gait, upper extremity, or core strength. Although another benefit of muscle flaps is that they provide bulk to fill wound dead space, fasciocutaneous flaps (like the SGAP flap) can provide a substantial volume of well-vascularized, septated adipofascial tissue that is also pliable enough to fill the large dead space that often accompany postoperative lumbar spinal wounds.

Although locoregional fasciocutaneous flaps can be used to reconstruct small or superficial lumbar defects, reconstruction of larger defects may necessitate provision of vascularized tissue from outside the zone of injury or radiation. More complex reconstructive procedures have been recommended for midline spinal wounds larger than 200 cm^2 .⁵⁷ For large defects, especially those with unavailable lumbar arterial and other regional angiosomes, reconstructive options include free flaps or pedicled flaps such as SGAP, gluteus maximus, and omental flaps. Although often discussed in the literature, free flap reconstruction can be limited by a paucity of viable vessels in the lumbar region for donor vessels, and the need for a secondary surgical site. Limitations on free flap pedicle length and lack of receptive lumbar vessels often necessitates the use of a vein graft, which can increase surgical

complexity and flap complications.⁵¹ In a large case series of 289 spine surgery patients, the use of a free flap reconstruction of the lumbar region was associated with a 12 times greater risk for wound complication than a local pedicled flaps.¹³ Comparatively, the pedicled SGAP flap may be ideal for reconstructing large lumbar defects as it has a reliable perforator, a large size of up to 13×28 cm, and a pedicle that is usually well outside the zone of injury and/or radiation, and no associated functional loss associated with flap harvest (as is the case with gluteus maximus muscle flaps).¹⁸

The SGAP flap is an appropriate reconstructive option for large lumbar wounds as it does not rely on the lumbar arteries, does not interfere with patient's ambulatory function, and is generally unaffected by prior lumbar radiation. It has been traditionally considered a technically difficult perforator flap to harvest; however, this can be ameliorated with careful planning and execution. In our experience, identification of perforator vessels should be based on knowledge of anatomy and intraoperative Doppler assessment. Preoperative computed tomography angiography may be considered in cases where prior surgery might have damaged the superior gluteal vessels, as is the case with partial or total sacrectomies, but often is not necessary. Our reconstructive team is often in close communication with our spine and general surgery colleagues to preserve the vascular pedicle for this flap during the extirpative portion of the procedure. During dissection, a bloodless field is ideal for visualization of the perforators. The flap is elevated from lateral to medial deep to the fascia of the gluteus maximus muscle toward origin of the superior gluteal artery between the piriformis and gluteus medius muscles, and all side branches are carefully ligated. The flap is raised and rotated, often between 120 and 180 degrees and then inset into the defect.

In our series, 3 patients required an additional operative intervention for infection or seroma, although all went on to completely heal their wounds. This complication rate reflects the complexity of reconstruction of large, radiated lumbar wounds with exposed hardware.

Lumbar spinal resection carries significant surgical-site morbidity, and selection of high-risk patients for immediate reconstruction with locoregional flap coverage, including SGAP flap coverage, may be beneficial for improving wound-related outcomes. In our case series, all but one of our SGAP flaps was performed in a delayed manner, with an average of 145 days before definitive reconstruction. Immediate soft-tissue reconstruction following spinal surgery has been shown to correlate with significantly lower rates of hardware removal, unplanned reoperations, and carry a lower mortality rate than delayed reconstruction.¹³ For complex lumbar defects, coordination with spine surgeons for prophylactic reconstruction with pedicled SGAP flaps might decrease complication rates and the need for reoperation.

CONCLUSIONS

The lumbar spine remains a challenging area for soft-tissue reconstruction. Many options exist for the reconstruction of lumbar defects, and the surgeon's approach

should be tailored based on wound and patient characteristics such as wound size, history of radiation, and ambulatory status. For large or radiated lumbar wounds, the pedicled SGAP flap is an excellent reconstructive choice as it has reliable anatomy, well-vascularized tissue outside the zone of injury, adequate bulk, and minimal functional donor-site deficits.

Kyle Eberlin, MD

Division of Plastic Surgery
Massachusetts General Hospital
55 Fruit Street
Boston, MA 02114
E-mail: keberlin@mgh.harvard.edu

REFERENCES

1. Wendt JR, Gardner VO, White JI. Treatment of complex post-operative lumbosacral wounds in nonparalyzed patients. *Plast Reconstr Surg.* 1998;101:1248–1253; discussion 1254. Available at <http://www.ncbi.nlm.nih.gov/pubmed/9529209>. Accessed September 3, 2018.
2. Casas LA, Lewis VL Jr. A reliable approach to the closure of large acquired midline defects of the back. *Plast Reconstr Surg.* 1989;84:632–641.
3. Eom JS, Hong JP. Lower back defect coverage using a free-style gluteal perforator flap. *Ann Plast Surg.* 2011;67:516–519. doi:10.1097/SAP.0b013e3182045823.
4. Ay A, Aytakin O, Aytakin A. Interdigitating fasciocutaneous gluteal V-Y advancement flaps for reconstruction of sacral defects. *Ann Plast Surg.* 2003;50:636–638.
5. Zeng A, Jia Y, Wang X, et al. The superior gluteal artery perforator flap for lumbosacral defect repair: a unified approach. *J Plast Reconstr Aesthet Surg.* 2013;66:e56–e57.
6. Kroll SS, Rosenfield L. Perforator-based flaps for low posterior midline defects. *Plast Reconstr Surg.* 1988;81:561–566. Available at <http://www.ncbi.nlm.nih.gov/pubmed/3279442>. Accessed September 3, 2018.
7. Evans GR, Reece GP. Lower back reconstruction: an approach to wound closure in the cancer patient. *Plast Reconstr Surg.* 1995;96:635–642. Available at <http://www.ncbi.nlm.nih.gov/pubmed/7638288>. Accessed September 3, 2018.
8. Ao M, Mae O, Namba Y, et al. Perforator-based flap for coverage of lumbosacral defects. *Plast Reconstr Surg.* 1998;101:987–991. Available at <http://www.ncbi.nlm.nih.gov/pubmed/9514331>. Accessed September 3, 2018.
9. Gözü A, Akkuş A, Seyithanoğlu H, et al. Versatility of perforator-based V-Y advancement flaps in reconstruction of complex mid back wounds. *Microsurgery.* 2011;31:229–233. doi:10.1002/micr.20847.
10. Roche NA, Van Landuyt K, Blondeel PN, et al. The use of pedicled perforator flaps for reconstruction of lumbosacral defects. *Ann Plast Surg.* 2000;45:7–14.
11. Arco G, Horch RE, Arkudas A, et al. Double pedicled perforator flap to close flank defects: an alternative for closure of a large lumbar defect after basalioma excision—a case report and review of the literature. *Ann Plast Surg.* 2009;63:422–424.
12. Mathur BS, Tan SS, Bhat FA, et al. The transverse lumbar perforator flap: an anatomic and clinical study. *J Plast Reconstr Aesthet Surg.* 2016;69:770–776.
13. Devulapalli C, Broyles JM, Bello R, et al. Soft-tissue reconstruction of large spinal defects: a 12-year institutional experience. *Plast Reconstr Surg.* 2017;140:806–814.
14. Dumanian GA, Ondra SL, Liu J, et al. Muscle flap salvage of spine wounds with soft tissue defects or infection. *Spine (Phila Pa 1976).* 2003;28:1203–1211. doi:10.1097/01.BRS.0000067260.22943.48.

15. Hultman CS, Jones GE, Losken A, et al. Salvage of infected spinal hardware with paraspinous muscle flaps: anatomic considerations with clinical correlation. *Ann Plast Surg.* 2006;57:521–528.
16. Manstein ME, Manstein CH, Manstein G. Paraspinous muscle flaps. *Ann Plast Surg.* 1998;40:458–462. Available at <http://www.ncbi.nlm.nih.gov/pubmed/9600427>. Accessed September 3, 2018.
17. Mericli AF, Tarola NA, Moore JH Jr, et al. Paraspinous muscle flap reconstruction of complex midline back wounds: risk factors and postreconstruction complications. *Ann Plast Surg.* 2010;65:219–224.
18. Moon SH, Choi JY, Lee JH, et al. Feasibility of a deepithelialized superior gluteal artery perforator propeller flap for various lumbosacral defects. *Ann Plast Surg.* 2015;74:589–593.
19. Cheon YW, Lee MC, Kim YS, et al. Gluteal artery perforator flap: a viable alternative for sacral radiation ulcer and osteoradionecrosis. *J Plast Reconstr Aesthet Surg.* 2010;63:642–647.
20. Mori H, Yano T, Tanaka K, et al. Two pedicled perforator flaps combined with a fascia graft for a large lateral lumbar defect. *J Plast Reconstr Aesthet Surg.* 2011;64:274–276.
21. Harris C, Damkat-Thomas L, Black CE. The superior gluteal artery perforator flap to reconstruct lumbar soft tissue defects in the non-ambulatory patient. *J Plast Reconstr Aesthet Surg.* 2012;65:408–409.
22. Onyekwelu O, Kosutic D. Double perforators-based superior gluteal artery propeller flap for reconstruction of lumbar defects. *Case Reports Plast Surg Hand Surg.* 2016;3:37–40.
23. Wong MC, Allison K, Yap LH, et al. The pedicled intercostal neurovascular island skin flap for lumbosacral trunk reconstruction. *Br J Plast Surg.* 2004;57:520–524.
24. Zang M, Yu S, Xu L, et al. Intercostal artery perforator propeller flap for reconstruction of trunk defects following sarcoma resection. *J Plast Reconstr Aesthet Surg.* 2015;68:822–829.
25. Hill C, Riaz M. A new twist to the myocutaneous turnover flap for closure of a spinal defect. *Plast Reconstr Surg.* 1998;102:1167–1170. Available at <http://www.ncbi.nlm.nih.gov/pubmed/9734439>. Accessed September 3, 2018.
26. Dirnberger F. The nontypical gluteus maximus flap. *Plast Reconstr Surg.* 1988;81:567–578. Available at <http://www.ncbi.nlm.nih.gov/pubmed/3347667>. Accessed September 3, 2018.
27. Frank CJ, Brantigan J, Cronan J. Bilateral interconnected latissimus dorsi-gluteus maximus muscular cutaneous flaps for closure of subfascial infections in lumbar spinal surgery. A technical note. *Spine (Phila Pa 1976).* 1997;22:564–567. Available at <http://www.ncbi.nlm.nih.gov/pubmed/9076890>. Accessed September 3, 2018.
28. Yanai A, Bandoh Y, Tsuzuki K. Bilateral gluteal thigh flaps for closure of large defects in the lumbosacral region and perineal region. *Plast Reconstr Surg.* 1991;88:703–706. Available at <http://www.ncbi.nlm.nih.gov/pubmed/1896544>. Accessed September 3, 2018.
29. Ramirez OM, Swartz WM, Futrell JW. The gluteus maximus muscle: experimental and clinical considerations relevant to reconstruction in ambulatory patients. *Br J Plast Surg.* 1987;40:1–10. Available at <http://www.ncbi.nlm.nih.gov/pubmed/3814892>. Accessed September 3, 2018.
30. de Fontaine S, Gaede F, Berthe JV. The reverse turnover latissimus dorsi flap for closure of midline lumbar defects. *J Plast Reconstr Aesthet Surg.* 2008;61:917–924.
31. Motegi S, Tamura A, Abe M, et al. Reverse latissimus dorsi musculocutaneous flap for reconstruction of lumbar radiation ulcer. *J Dermatol.* 2007;34:565–569.
32. Cigna E, Mardini S, Chen H-C, et al. An improved method of supercharged transposed latissimus dorsi flap with the skin paddle for the management of a complicated lumbosacral defect. *Eur Rev Med Pharmacol Sci.* 2015;19:921–926. Available at <http://www.ncbi.nlm.nih.gov/pubmed/25855913>. Accessed September 3, 2018.
33. Liu Y, Yu S, Song B, et al. Reconstruction of posterior lumbar defects in oncologic patients using two island flaps of the back in series. *Ann Plast Surg.* 2010;65:326–329.
34. Yamamoto N, Igota S, Izaki H, et al. Reverse turnover transfer of a latissimus dorsi muscle flap to a large lumbar defect. *Plast Reconstr Surg.* 2001;107:1496–1499. Available at <http://www.ncbi.nlm.nih.gov/pubmed/11335825>. Accessed September 3, 2018.
35. Klink BK, Thurman RT, Wittpenn GP, et al. Muscle flap closure for salvage of complex back wounds. *Spine (Phila Pa 1976).* 1994;19:1467–1470. Available at <http://www.ncbi.nlm.nih.gov/pubmed/7939976>. Accessed September 3, 2018.
36. Narushima M, Yamamoto T, Yamamoto Y, et al. Lateral intercostal artery perforator-based reversed thoracodorsal artery flap for reconstruction of a chronic radiation ulcer of the lower back wall. *Ann Plast Surg.* 2011;67:352–356.
37. Sakai S, Soeda S, Matsukawa A. External oblique musculocutaneous flap for the reconstruction of a lumbo-sacral defect. *Br J Plast Surg.* 1988;41:551–553. Available at <http://www.ncbi.nlm.nih.gov/pubmed/3179601>. Accessed September 3, 2018.
38. Ladin D, Rees R, Wilkins E, et al. The use of omental transposition in the treatment of recurrent sarcoma of the back. *Ann Plast Surg.* 1993;31:556–559. Available at <http://www.ncbi.nlm.nih.gov/pubmed/8297090>. Accessed September 3, 2018.
39. Lantieri LA, Tantaoui B, Rimareix FA, et al. Lower back coverage with endoscopically harvested pedicled greater omental flap. *Plast Reconstr Surg.* 1999;103:960–963. Available at <http://www.ncbi.nlm.nih.gov/pubmed/10077088>. Accessed September 3, 2018.
40. Schmidek AK, Warren SM, Tantillo MB, et al. Salvage treatment of an irradiated, infected lumbosacral wound. *Ann Plast Surg.* 2005;55:531–534. Available at <http://www.ncbi.nlm.nih.gov/pubmed/16258309>. Accessed September 3, 2018.
41. Hung SJ, Chen HC, Wei FC. Free flaps for reconstruction of the lower back and sacral area. *Microsurgery.* 2000;20:72–76. Available at <http://www.ncbi.nlm.nih.gov/pubmed/10702740>. Accessed September 3, 2018.
42. Mureau MA, Hofer SO. Perforator-to-perforator musculocutaneous anterolateral thigh flap for reconstruction of a lumbosacral defect using the lumbar artery perforator as recipient vessel. *J Reconstr Microsurg.* 2008;24:295–299.
43. Mustonen PK, Härmä MA, Berg MH, et al. Microvascular myocutaneous flaps in the lumbosacral area using the iliac artery and vein as recipient vessels. *Br J Plast Surg.* 2002;55:514–516. Available at <http://www.ncbi.nlm.nih.gov/pubmed/12479429>. Accessed September 3, 2018.
44. Pannucci C, Gerety P, Nelson J, et al. Use of intercostal perforating veins and long arterial grafts for latissimus myocutaneous free flap reconstruction of radiated low back wounds. *J Reconstr Microsurg.* 2015;31:396–400. doi:10.1055/s-0035-1546293.
45. Park S, Koh KS. Superior gluteal vessel as recipient for free flap reconstruction of lumbosacral defect. *Plast Reconstr Surg.* 1998;101:1842–1849. Available at <http://www.ncbi.nlm.nih.gov/pubmed/9623825>. Accessed September 3, 2018.
46. Sinis N, Lanaras TI, Kraus A, et al. Free latissimus dorsi flap with long venous grafts for closure of a soft tissue defect of the spine in a patient with Noonan's syndrome: a case report. *Microsurgery.* 2009;29:486–489. doi:10.1002/micr.20625.
47. Tuncer S, Uygur S, Kaya B, et al. Reconstruction of a lumbosacral defect using free latissimus dorsi flap with arteriovenous-loop: impact of preserving serratus branch temporarily. *Int Wound J.* 2015;12:613–614.
48. Zhu S-X, Chang B-X, Lu S-B. Free transfer of latissimus dorsi myocutaneous flap using wrist vessels as carriers for the treat-

- ment of lumbo-sacral scar contracture deformity. *Eur J Plast Surg*. 1987;9:167–168. doi:10.1007/BF00452774.
49. Acarturk TO, Glaser DP, Newton ED. Reconstruction of difficult wounds with tissue-expanded free flaps. *Ann Plast Surg*. 2004;52:493–499; discussion 500. Available at <http://www.ncbi.nlm.nih.gov/pubmed/15096936>. Accessed September 3, 2018.
 50. Arkudas A, Horch RE, Regus S, et al. Retrospective cohort study of combined approach for trunk reconstruction using arteriovenous loops and free flaps. *J Plast Reconstr Aesthet Surg*. 2018;71:394–401.
 51. Di Benedetto G, Bertani A, Pallua N. The free latissimus dorsi flap revisited: a primary option for coverage of wide recurrent lumbosacral defects. *Plast Reconstr Surg*. 2002;109:1960–1965.
 52. Duteille F, Perrot P, Floch N, et al. Advantages of using intercostal vessels as the recipients for free flaps covering lumbar defects. *J Reconstr Microsurg*. 2004;20:523–526.
 53. Gaster RS, Bhatt KA, Shelton AA, et al. Free transverse rectus abdominis myocutaneous flap reconstruction of a massive lumbosacral defect using superior gluteal artery perforator vessels. *Microsurgery*. 2012;32:388–392.
 54. Giesswein P, Constance CG, Mackay DR, et al. Supercharged latissimus dorsi muscle flap for coverage of the problem wound in the lower back. *Plast Reconstr Surg*. 1994;94:1060–1063. Available at <http://www.ncbi.nlm.nih.gov/pubmed/7972461>. Accessed September 3, 2018.
 55. Harris GD, Lewis VL, Nagle DJ, et al. Free flap reconstruction of the lower back and posterior pelvis: indications, principles, and techniques. *J Reconstr Microsurg*. 1988;4:169–178.
 56. Iwakiri K, Miyauchi A, Okuda S, et al. Lumbosacral reconstruction for intractable pyogenic spondylitis using a total leg flap with a vascularized tibia graft. *J Neurosurg Spine*. 2008;8:468–472.
 57. Few JW, Marcus JR, Lee MJ, et al. Treatment of hostile midline back wounds: an extreme approach. *Plast Reconstr Surg*. 2000;105:2448–2451.
 58. Haapamäki MM, Pihlgren V, Lundberg O, et al. Physical performance and quality of life after extended abdominoperineal excision of rectum and reconstruction of the pelvic floor with gluteus maximus flap. *Dis Colon Rectum*. 2011;54:101–106.
 59. Cho EH, Shammam RL, Carney MJ, et al. Muscle versus fasciocutaneous free flaps in lower extremity traumatic reconstruction: a multicenter outcomes analysis. *Plast Reconstr Surg*. 2018;141:191–199.
 60. Yazar S, Lin CH, Lin YT, et al. Outcome comparison between free muscle and free fasciocutaneous flaps for reconstruction of distal third and ankle traumatic open tibial fractures. *Plast Reconstr Surg*. 2006;117:2468–2475; discussion 2476.